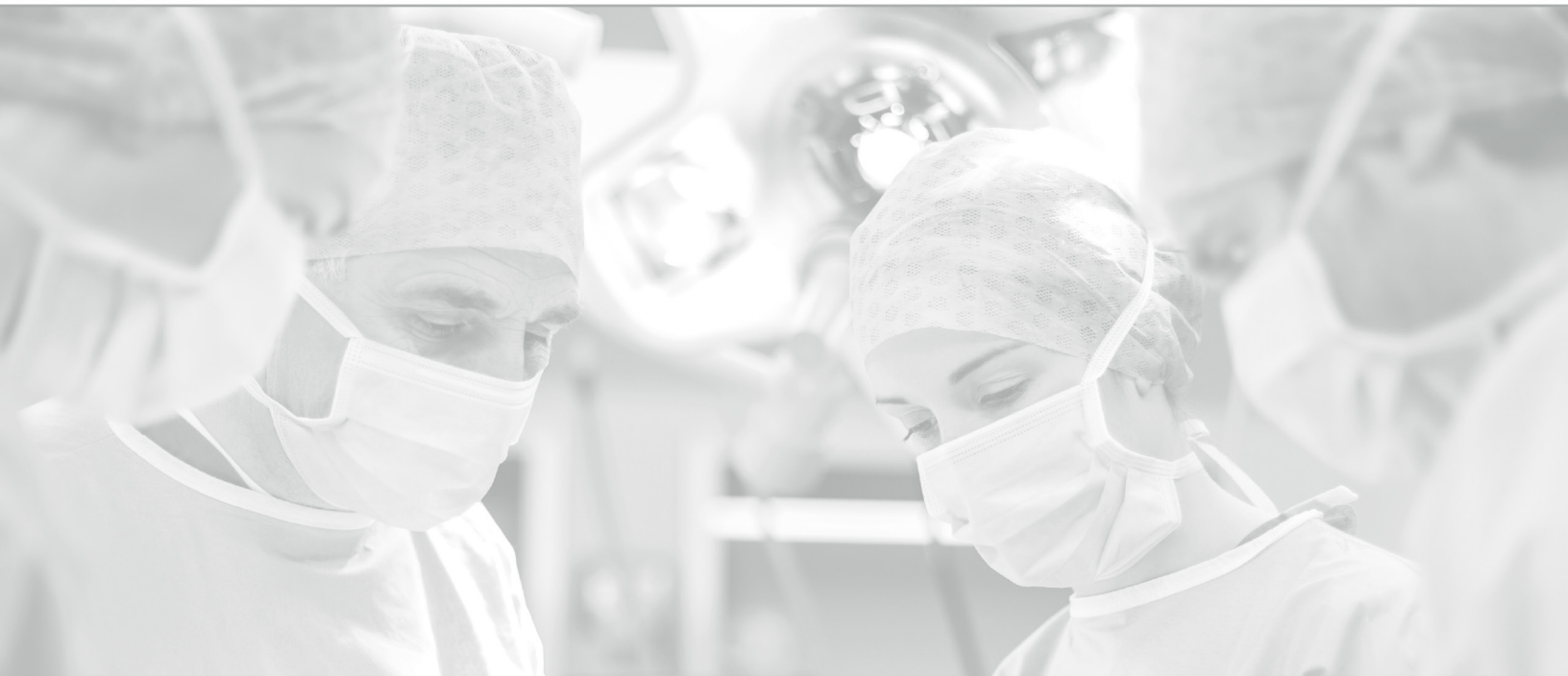

Tornier Approach

Shoulder Arthroplasty Program

Operative technique



This publication sets forth detailed recommended procedures for using Stryker devices and instruments. It offers guidance that you should heed, but, as with any such technical guide, each surgeon must consider the particular needs of each patient and make appropriate adjustments when and as required.

Important

- The patient should be advised that the device cannot and does not replicate a normal healthy bone, that the device can break or become damaged as a result of strenuous activity or trauma and that the device has a finite expected service life.
- Removal or revision of the device may be required sometime in the future.
- Cleaning and sterilization information is provided in the applicable instructions for use.
- Non-sterile devices, including implants and instruments, must be cleaned and sterilized prior to use, in accordance with validated methods.
- Devices that are able to be disassembled should be disassembled prior to point-of-use processing. Additionally, devices with movable components that do not facilitate disassembly should be manually articulated during the point-of-use processing step in order to evacuate additional soils.
- Please remember that the compatibility of different product systems has not been tested unless specified otherwise in the product labeling.
- Consult Instructions for Use (<https://ifu.stryker.com>) for a complete list of potential adverse effects and adverse events, contraindications, warnings and precautions.
- The surgeon must advise patients of surgical risks, and make them aware of adverse effects and alternative treatments.
- An implant whose packaging is open or damaged or whose expiration date has passed must not be used. Every precaution must be taken to ensure sterility when opening the packaging of the implant and during implantation.

Tornier Approach

Shoulder Arthroplasty Program

Table of contents

Operating room and patient set-up.....	4
• Operating room set-up	4
• Mayo stand and back table set-up	5
• Patient positioning	6
• Sterile prep	7
• Draping	7
Approach	8
• Skin incision	8
• Cephalic vein and deltopectoral interval identification	9
• Coracoid and conjoined tendon identification	10
• Pectoralis major incision	12
• Biceps tenodesis	12
• Locating the rotator interval.....	13
• Ligation of the anterior humeral circumflex vessels	14
Subscapularis release	15
• Tag sutures in the subscapularis	15
Humeral preparation	18
• Humeral instrumentation	21
Establish glenoid exposure	23
• Coracohumeral and glenohumeral ligament releases	23
• Anterior labrum release	26
• Inferior capsule release	26
• Posterior releases	27
Glenoid instrumentation.....	28
• Anatomic glenoid instrumentation	28
• Reversed glenoid instrumentation	29
• Final humeral implantation	30
Reduction, subscapularis and rotator interval closure.....	31
Pectoralis and deltopectoral interval closure	35
Wound closure	36
System components	37
Instrument ordering information	38

Operating room and patient set-up

Operating room set-up

The surgical team assembled should include a team of three medical professionals – surgeon, first assistant and scrub tech. The first assistant should be located at the head of the patient on the operative side. The scrub tech should be on the opposite side of the bed. | **Figure 1**

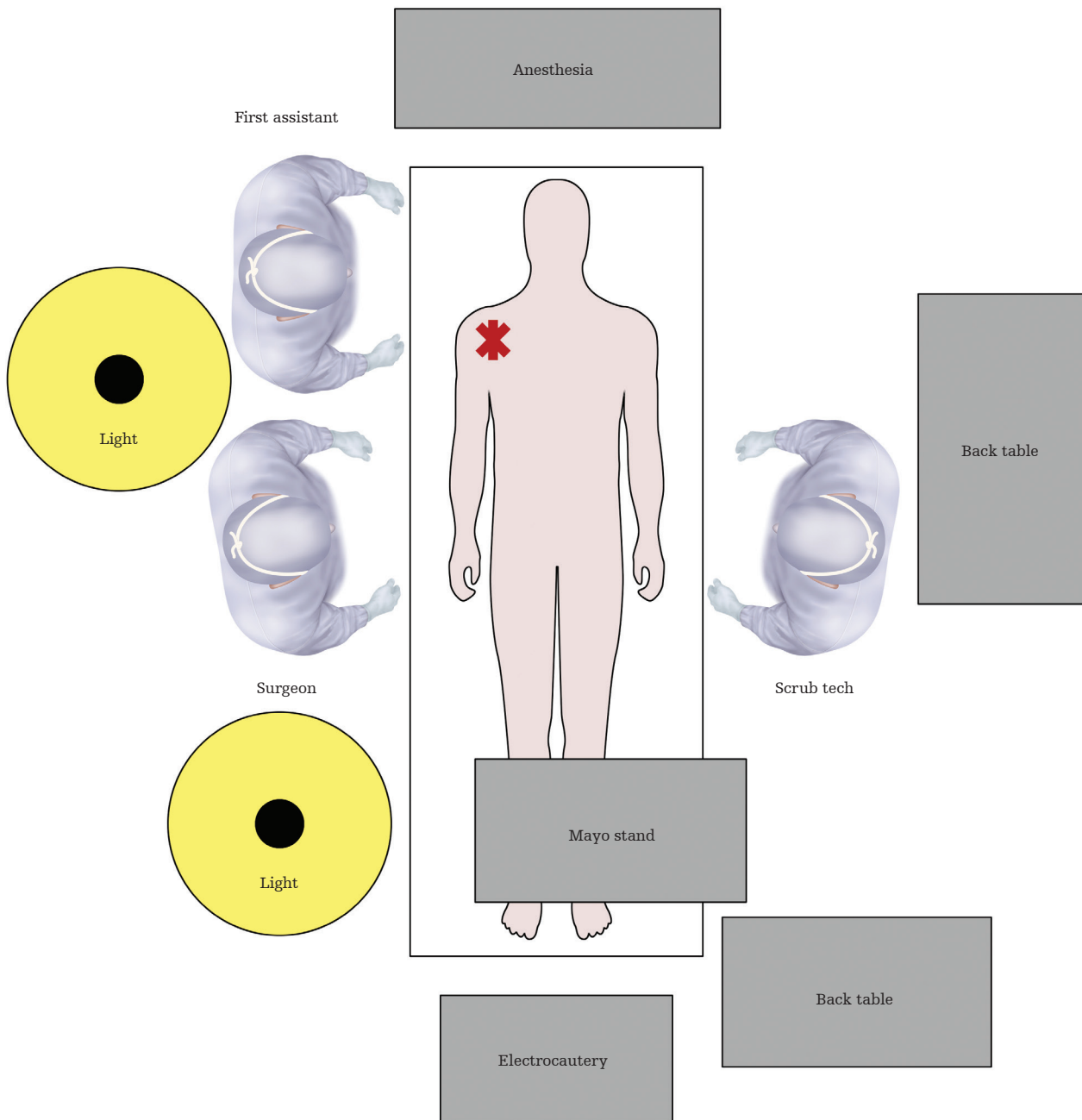


Figure 1
OR set-up

Mayo stand and back table set-up

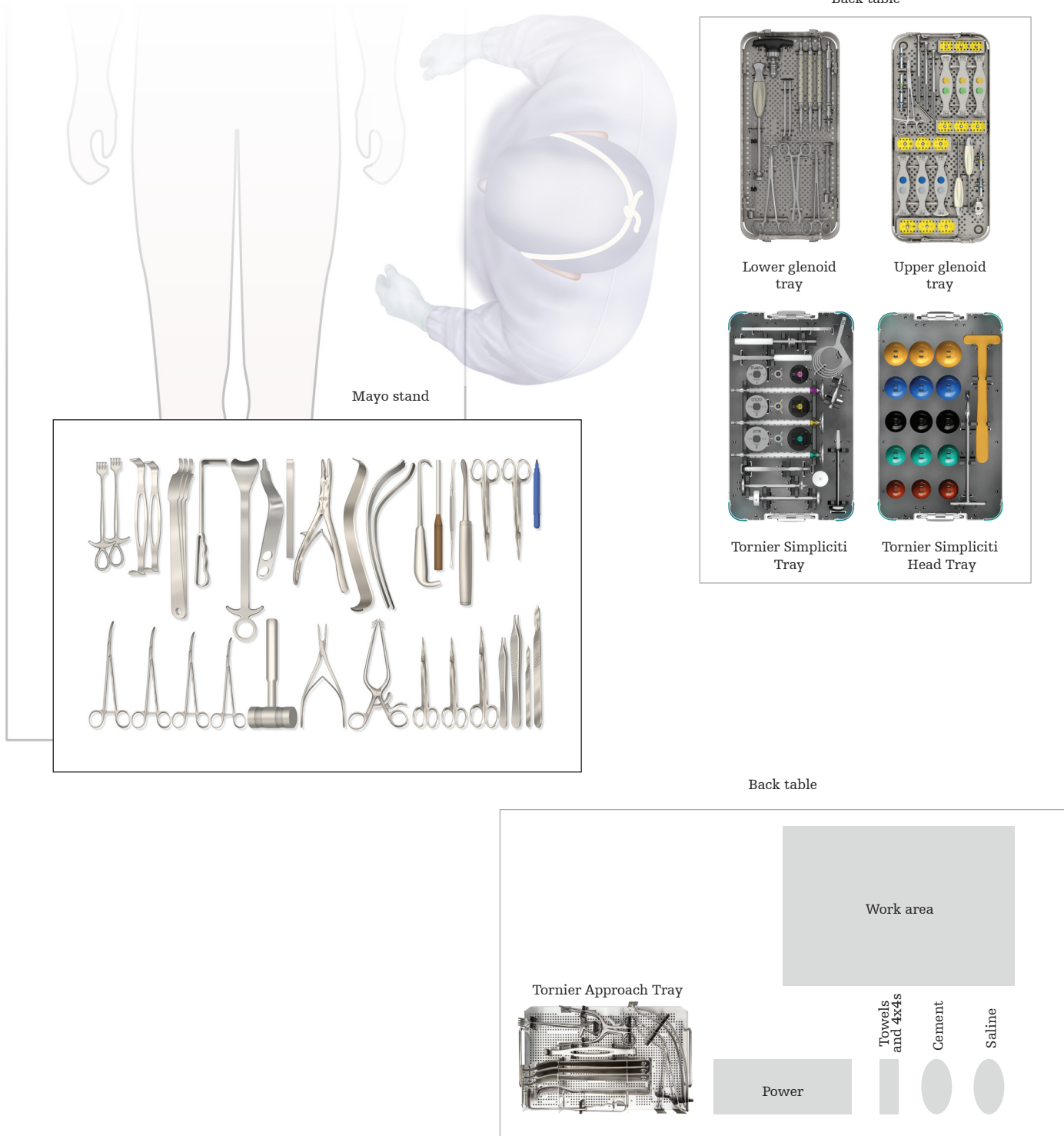


Figure 2
Mayo stand and back table set-up

Operating room and patient set-up

Patient positioning

The procedure should be on a standard operating room bed that can be adjusted to be in the modified beach chair position. Additionally, the bed should contain the following:

- Large strap that will go under the axilla
- Strap for the well-padded, non-operative arm
- Leg strap for patient security
- Bed sheet folded in half the long way across the bed, which will be placed under the patient in the steps to follow
- Head pad to rest patient's head

Before bringing the patient into the operating room, ensure that the operative arm hair has been shaved down to the elbow. The armpit does not need to be shaved.

Prior to sliding the patient onto the bed, ensure that the sheet is under them. Upon sufficiently placing the patient at the head of the bed, slide them to the operative side so that the operative extremity is off of the edge of the bed, allowing appropriate arm extension and adduction.

Place the folded sheet bump under the midline of the patient, in-between the scapulae. **This is a key step for future glenoid and humeral exposure.** Place the bed in a modified beach chair position:

- Reflex the bed
- Tilt the head back/down slightly
- Position the legs down to relax patient's hamstrings, using pads and/or pillows under the calves
- The final position should put the back of the patient at 45-60 degrees relative to the floor

Once final body position has been established, secure the straps around the patient, and then secure the head of the patient in place. Ensure that the patient's head and neck are well padded, while resting in a neutral position. | **Figure 3**

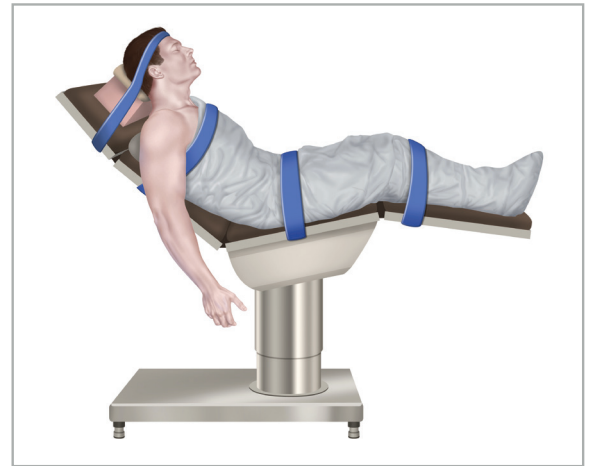

Figure 3
Patient positioning

Sterile prep

Clean the operative arm (including the axilla) with alcohol using gauze or an operating room towel prior to sterile prep.

After cleaning, perform a sterile prep of the operative arm in the standard fashion.

Draping

Tuck a single sheet into the strap in the axilla. Use a sterile stockinet and adhesive wrap for the operative arm. The stockinet should come proximal to the elbow. When performing revision arthroplasty, the stockinet should be positioned closer to the elbow in case the incision needs to be extended distally.

A sterile towel should be used to wipe and create a dry area for the sticky plastic U-drape.

Apply the sticky plastic U-drape.

Use a second sterile towel to wipe and create a dry area for the split U-drape. Apply the split U-drape on the axilla side and then apply it with plastic from the cranial side.

Use a marking pen to draw out the tip of the coracoid and approximate location of the deltopectoral interval for the planned incision. | **Figure 4** The deltopectoral interval can be approximated by directing the mark from the tip of the coracoid toward the deltoid insertion on the humerus. The incision should be 10cm-15cm in length.

Apply iodine impregnated occlusive dressing (in patients with no iodine allergy) or non-iodine impregnated occlusive dressing (in patients with iodine allergy) to cover all exposed skin, including the axilla. Change outer gloves after the draping is completed.

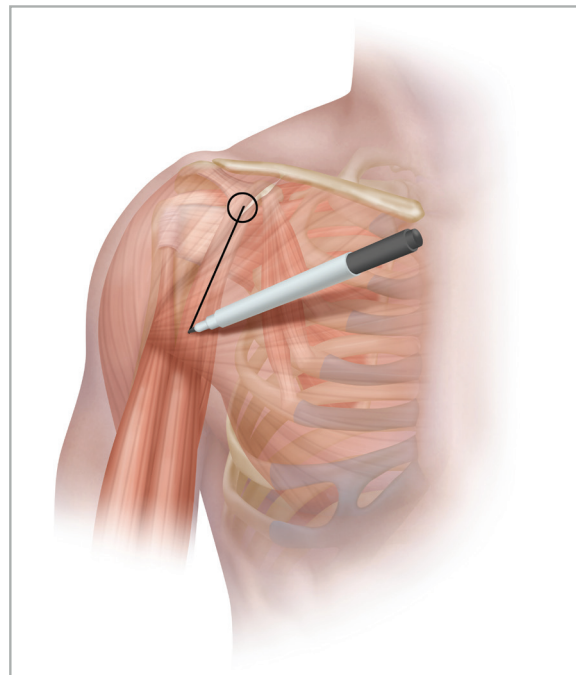


Figure 4
Marking the deltopectoral incision

Approach

Skin incision

Essential retractors:

2 long skin rakes

Place the arm in neutral rotation with the elbow flexed. Use a #10 blade on a regular handle to begin the planned skin incision. | **Figure 5**

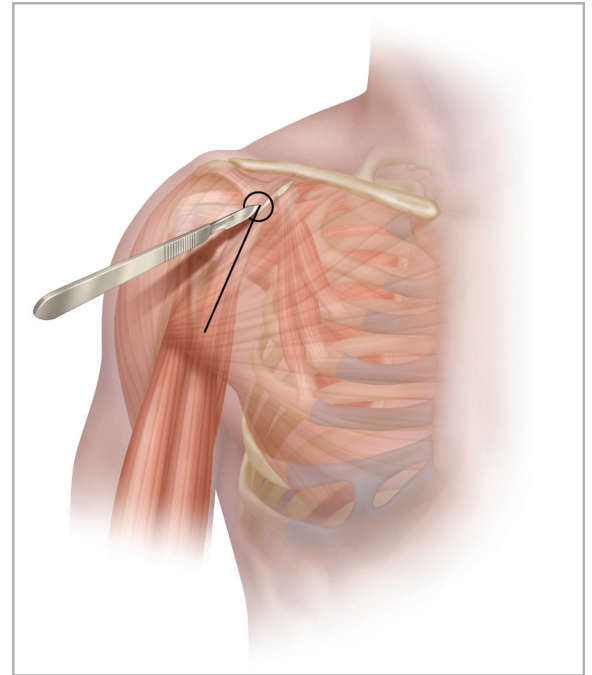


Figure 5
Skin incision

Place two large skin rakes on both sides of the incision to provide appropriate tension for dissection. | **Figure 6** Assistant will hold both skin rakes in place. Continue to dissect with electrocautery until the fat stripe overlying the cephalic vein is identified.

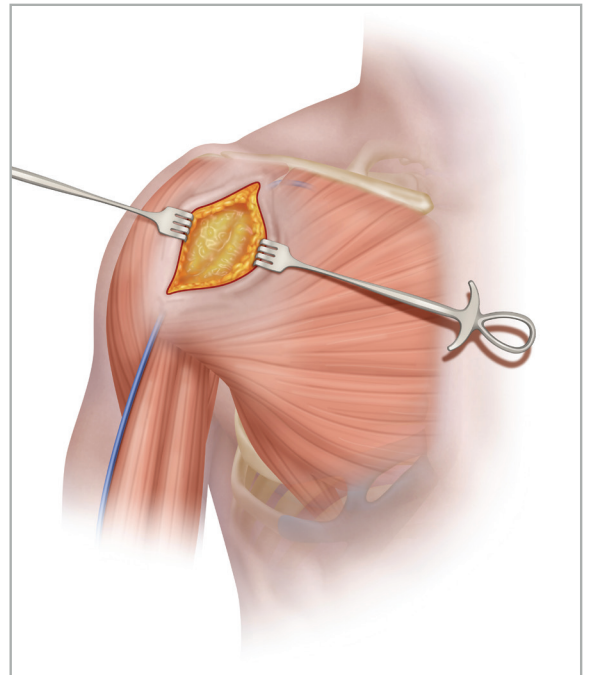


Figure 6
Skin rake placement

Cephalic vein and deltopectoral interval identification

Essential retractors:

- 2 skin rakes
- 2 Army-Navy

Using metzenbaum scissors and vascular forceps, dissect the cephalic vein to identify the deltopectoral interval. | **Figure 7** To fully develop the interval, bluntly dissect between the muscles.

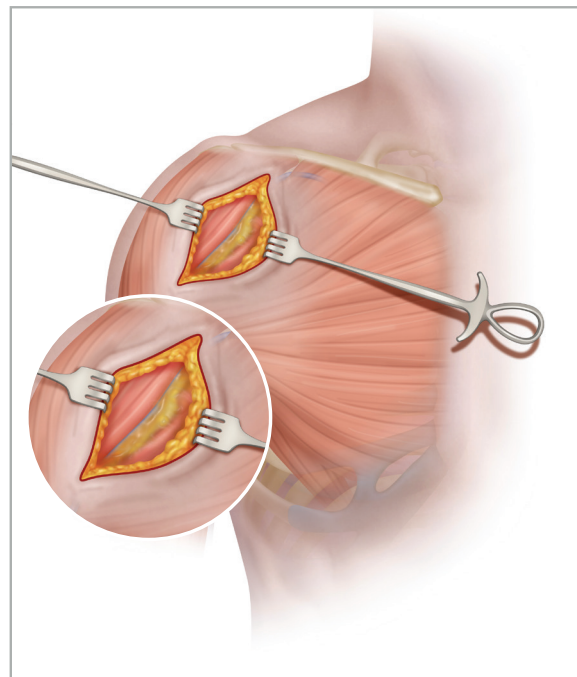


Figure 7
Exposure of cephalic vein

Remove the lateral skin rake. Place an Army-Navy retractor to retract the cephalic vein laterally with the deltoid. Remove the other skin rake and place a second Army-Navy retractor to retract the pectoralis major medially. | **Figure 8** Assistant should hold both Army-Navy retractors.

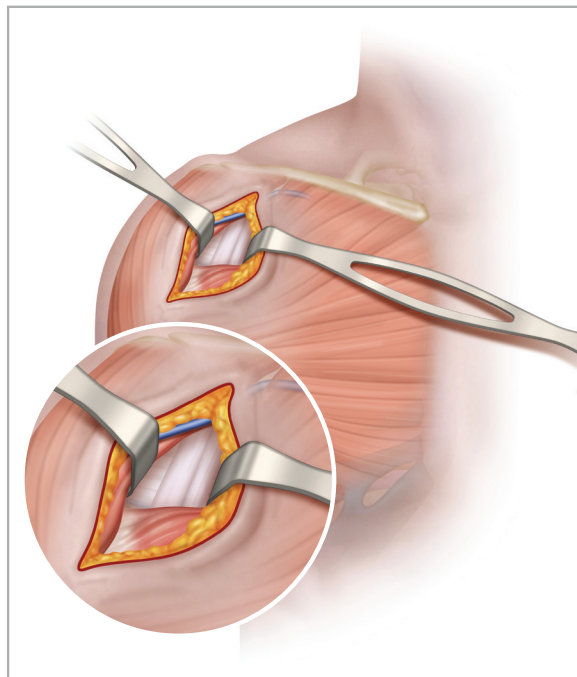


Figure 8
Deltoid and pectoralis muscle retraction

Approach

Coracoid and conjoined tendon identification

Essential retractors:

- 1 large Hohmann
- 1 Richardson
- 2 Army-Navy

It may be necessary to place a Hohmann superiorly over the coracoid to improve visibility for larger patients. To best position the retractor, adduct and externally rotate the arm and then hand the arm to the assistant. Insert large curved Mayo scissors over the top of the coracoid and spread open to create space for the retractor. | **Figure 9**

Place the large Hohmann retractor above the coracoid and hand to assistant. | **Figure 10** This retractor may be taped and clamped to the draping to hold in position.

Return the operative arm back to neutral, where it will again be controlled by the surgeon. Proceed with electrocautery along the clavicular fascia and the lateral edge of the conjoined tendon. | **Figure 11**

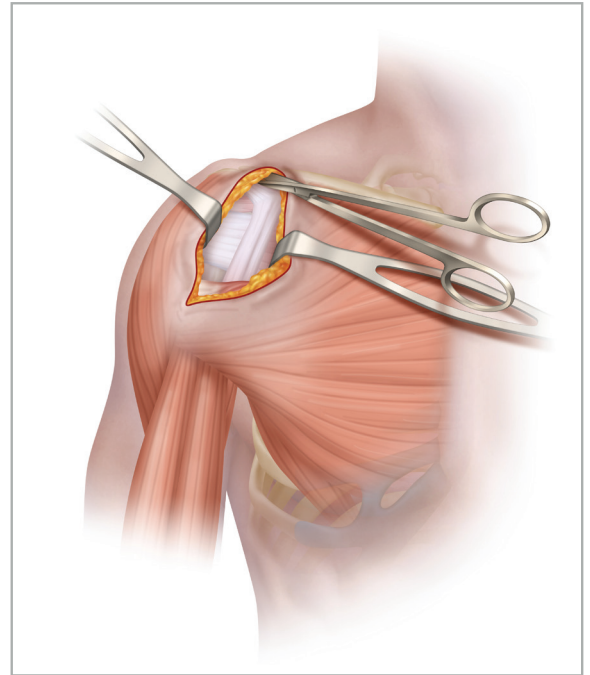


Figure 9
Insertion of curved Mayo scissors over coracoid

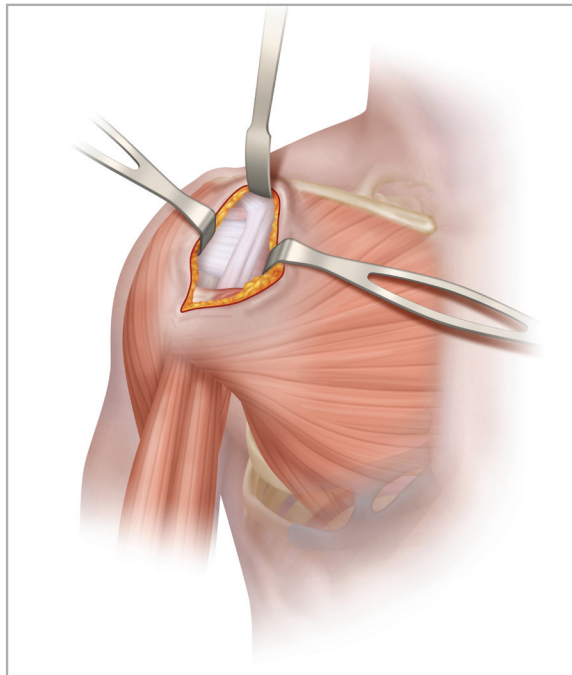


Figure 10
Positioning of large Hohmann over coracoid

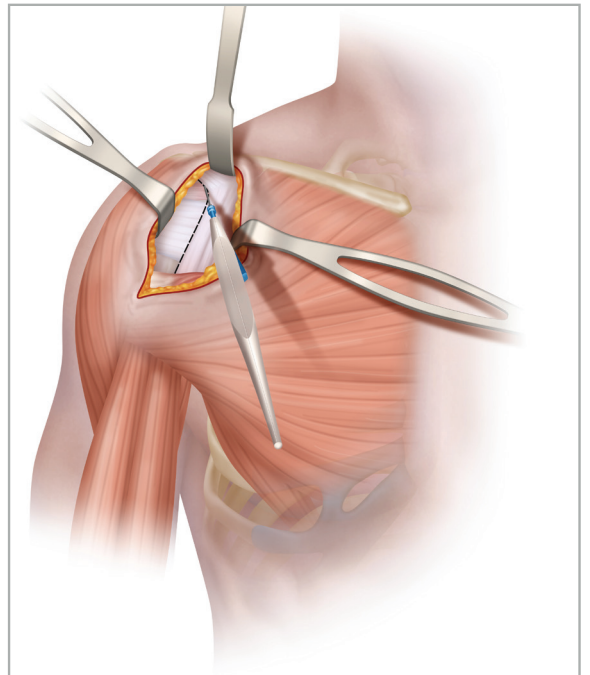


Figure 11
Clavicular fascia release

Forward flex the arm and place the Richardson retractor under the conjoined tendon and gently retract it medially. | **Figure 12** Either the assistant or the scrub tech on the opposite side of the bed will hold the Richardson retractor in place.

Note: Be careful not to place excessive retraction pressure on the musculocutaneous nerve underlying the conjoined tendon.

At this point, proceed with releasing any sub-deltoid adhesions. To begin, abduct the arm to release tension from the deltoid. Use a finger or blunt instrument (i.e., Hohmann or Darrach) to sweep under the deltoid and release underlying adhesions. | **Figure 13**

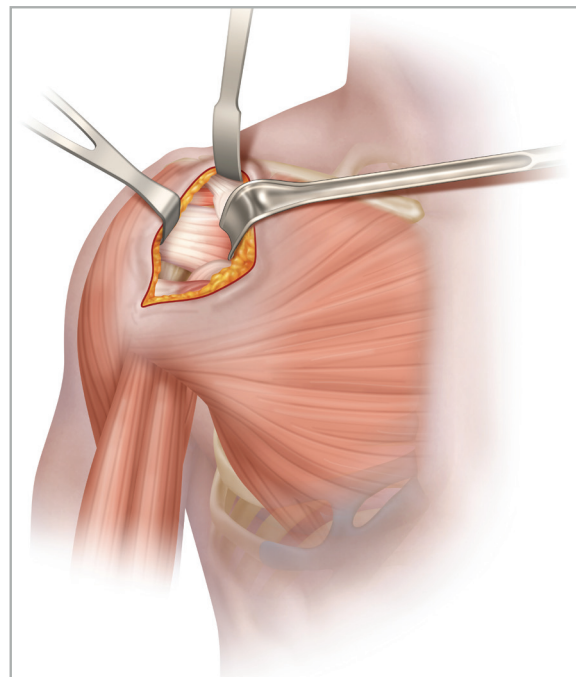


Figure 12
Retraction of conjoined tendon

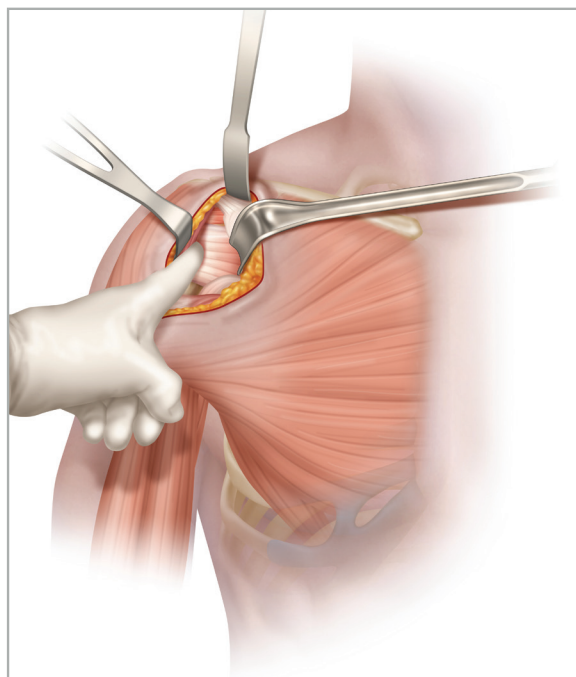


Figure 13
Release of sub-deltoid adhesions

Approach

Pectoralis major incision

With the arm in neutral position and the elbow flexed, locate the superior aspect of the pectoralis major and use electrocautery and vascular forceps to release the upper 1cm close to its insertion on the humerus (just above the underlying biceps tendon). | **Figure 14**

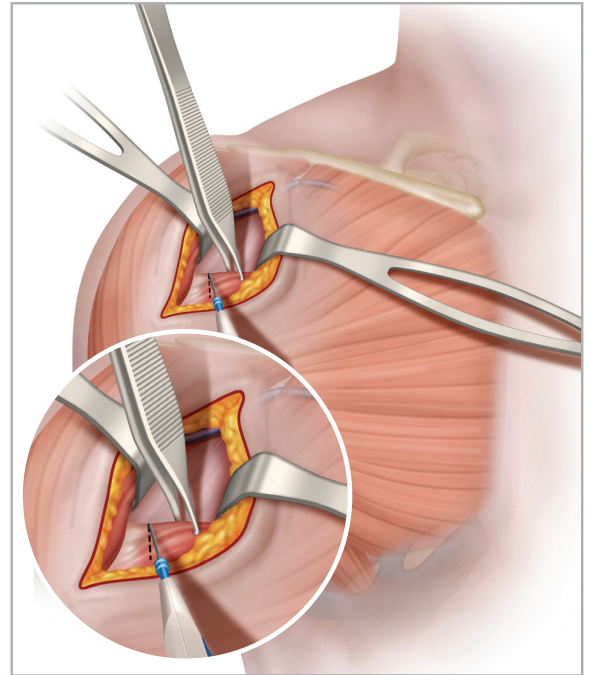


Figure 14
Pectoralis major release

Biceps tenodesis

Identify the biceps tendon located directly below the pectoralis incision. Suture the biceps tendon into the superior border of the pectoralis major using #2 non-absorbable suture. | **Figure 15**

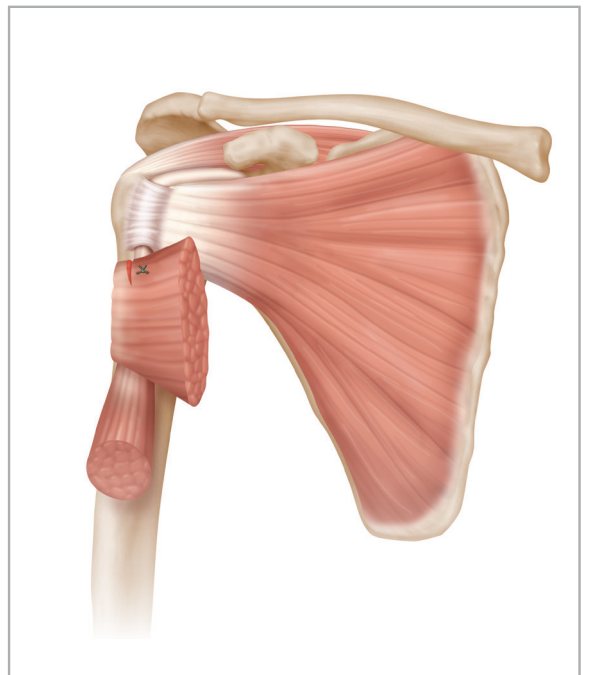


Figure 15

Locating the rotator interval

The path of the biceps tendon can be used to identify the rotator interval. Use Mayo scissors to follow the path of the biceps tendon through the bicipital groove, medial across the superior border of the subscap, and push the tip of the scissors into the rotator interval. | **Figure 16** Joint fluid will then release from the capsule.

The biceps tendon can then be cut at the level of the rotator interval and again just above the location of the tenodesis to the pec major for removal. | **Figure 17** The remaining proximal biceps stump will be removed once glenoid exposure is established.

If desired, a biceps tenotomy can also be performed by simply cutting the biceps tendon at the level of the rotator interval.

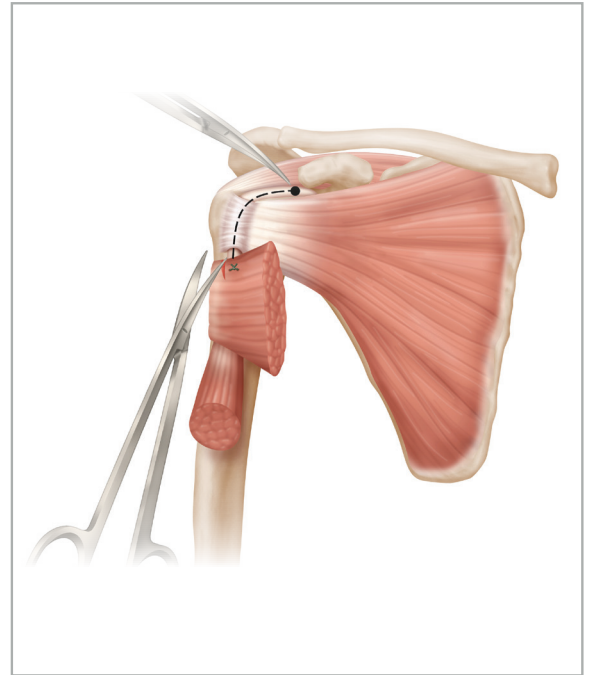


Figure 16

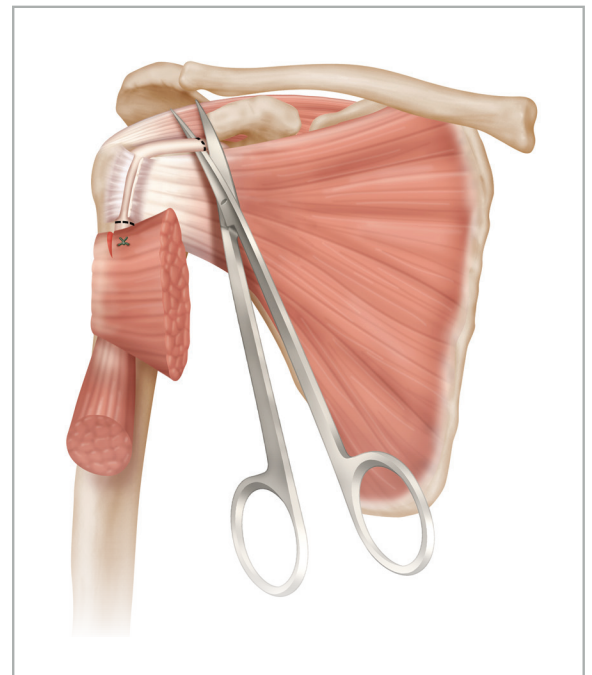


Figure 17

Approach

Ligation of the anterior humeral circumflex vessels

Essential retractors:

- 1 large Hohmann
- 1 Army-Navy

Move the Richardson retractor more distally along the conjoined tendon to better expose the anterior humeral circumflex vessels (aka “three sisters”).
| **Figures 18A and 18B** Approximate the location of the anatomic neck. Use a vascular forceps and 0 dyed vicryl stitch to place the first ligation stitch around the anterior humeral circumflex vessels, medial to the approximate location of the anatomic neck. Cut the stitch so that a 1cm tag remains. Place a second stitch around where the lateral aspect of the anatomical humeral neck is. The long tags and dyed color on the stitches will allow for easier identification when using the electrocautery between them during the subscapularis tenotomy step.

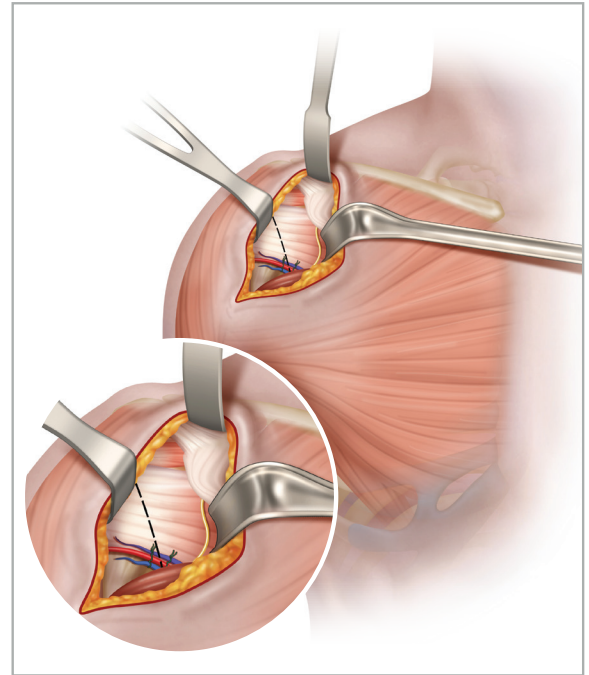


Figure 18A
Ligation of circumflex vessels

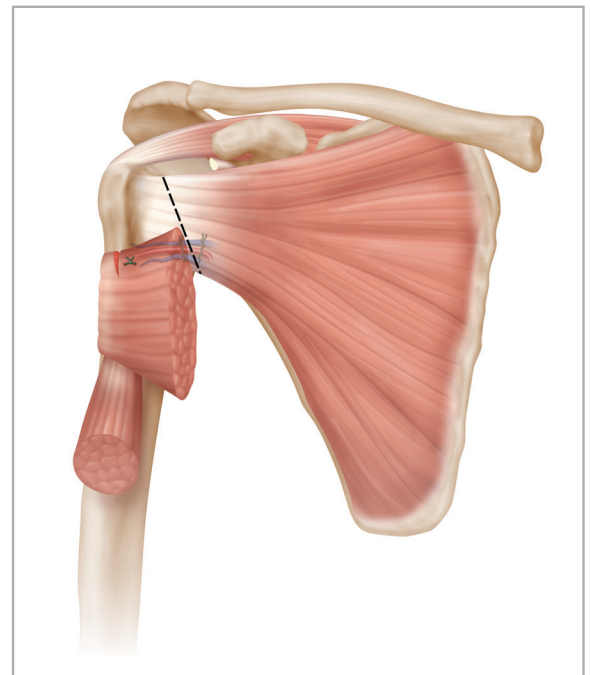


Figure 18B

Subscapularis release

Tag sutures in the subscapularis

Essential retractors:

- 1 large Hohmann
- 1 Army-Navy
- 1 Richardson

With the arm in the adducted and externally rotated position, move the Richardson retractor slightly proximal to fully identify the subscapularis.

Use #1 vicryl absorbable suture to place the first tag suture in the superior half of the tendon (from superior to inferior) in a mattress fashion. Place a second tag suture more inferiorly (again, starting from superior to inferior) in a mattress fashion. Use a hemostat to grasp all 4 limbs of the tag sutures and cut them at equal length. | **Figure 19**

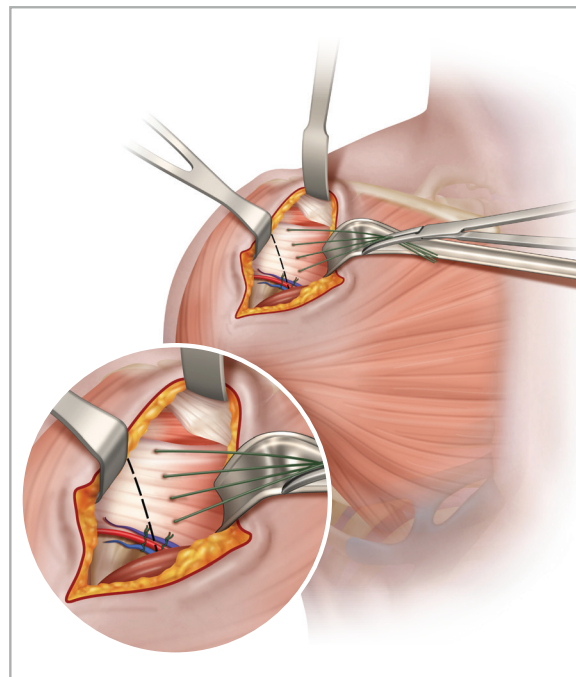


Figure 19
Placement of subscapularis tag sutures

Subscapularis release

With the arm adducted and slightly externally rotated, use heavy forceps to push the rotator interval tissue out of the way and a fresh 10-blade to release the superior two-thirds of the subscapularis, medial to the lesser tuberosity, following along the anatomic neck. | **Figure 20A** As you continue down to the inferior one-third, switch to electrocautery and continue down through the middle of the two dyed vicryl sutures placed around the anterior circumflex vessels. | **Figure 20B** The assistant should gradually externally rotate the arm as the surgeon moves inferiorly through the circumflex suture ligations and releases the inferior capsule from the humerus.

Note: Pay close attention not to error too medially with the incision, as this can result in a muscle-to-muscle repair needing to be done at the end of the procedure.

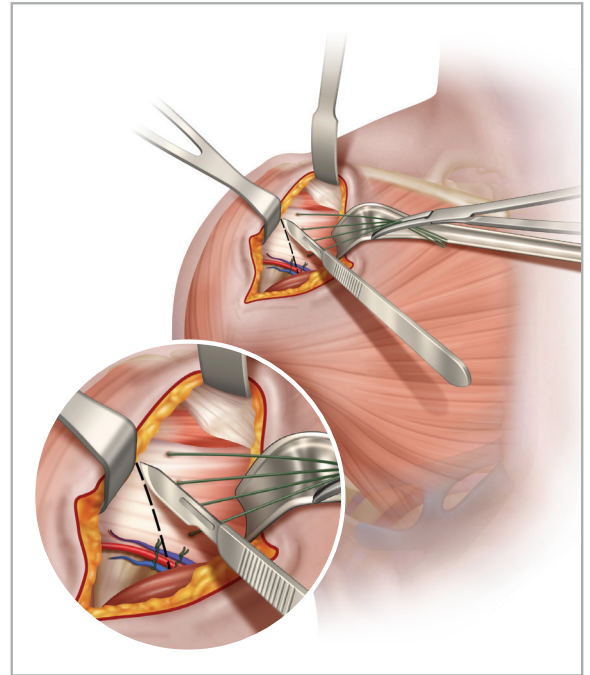


Figure 20A
Superior subscapularis release with scalpel

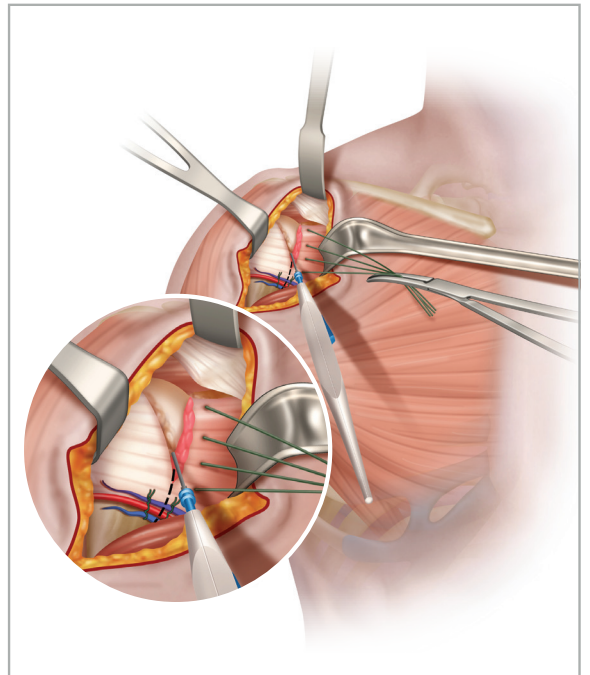


Figure 20B
Completing subscapularis release with cautery

Continue releasing the capsule to expose the medial calcar of the humerus, staying right on the bone while doing so. Continue to have the assistant progressively externally rotate the arm to assist in visualizing and releasing the inferior capsule. | **Figures 21A, 21B, and 21C**

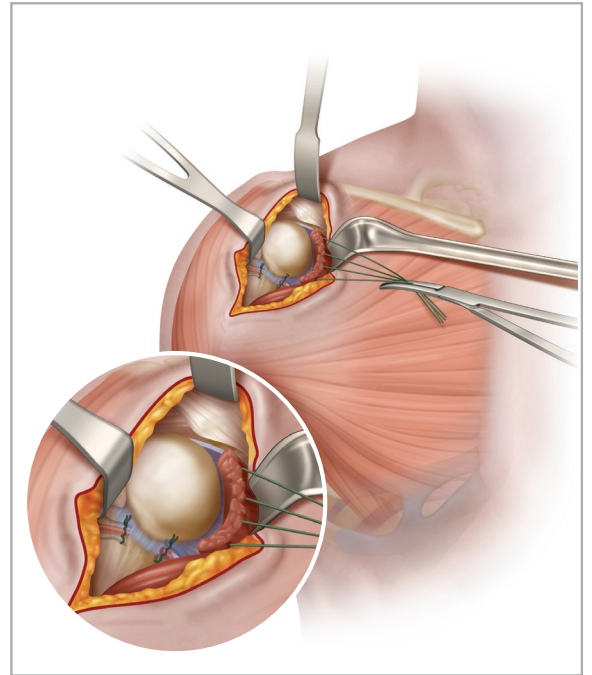


Figure 21A
Humeral capsular release

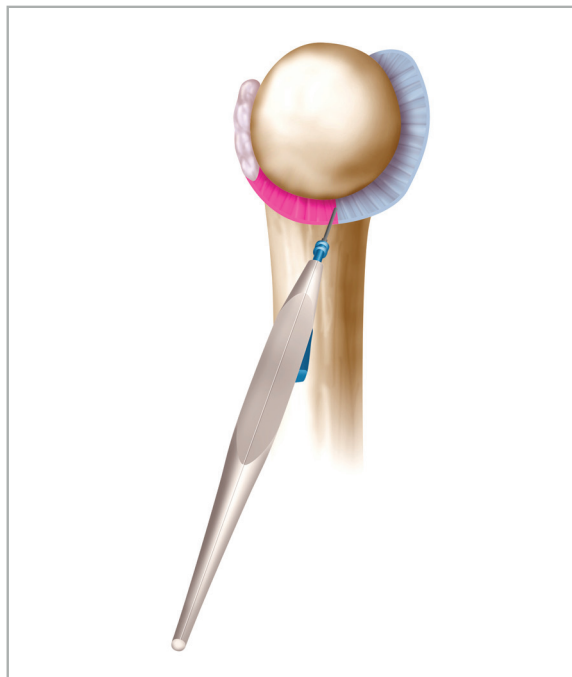


Figure 21B
Extent of medial calcar capsular release

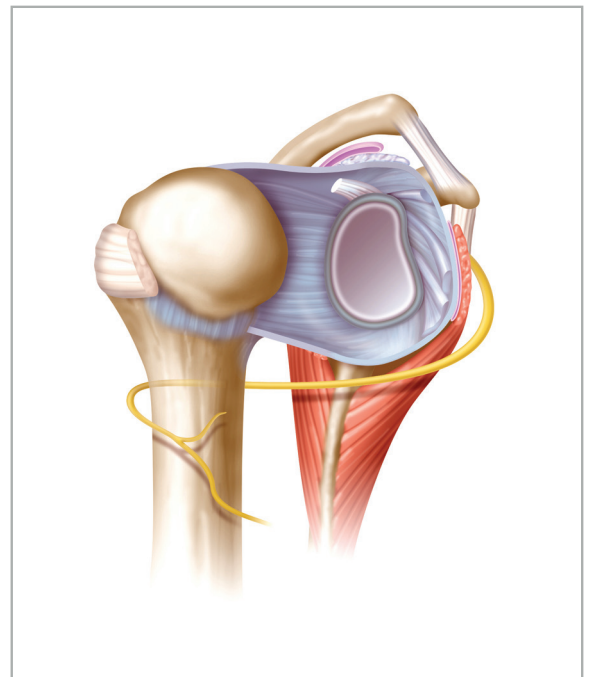


Figure 21C
Result of comprehensive capsular release from humerus

Humeral preparation

Essential retractors:

- 1 large Hohmann
- 1 Browne deltoid
- 1 reverse Hohmann

Remove the large Hohmann, Army-Navy and Richardson.

Externally rotate and extend the arm to dislocate the shoulder. Upon dislocation, adduct the arm to expose the humeral head. The assistant should then maintain the position of the arm.

Place one (or two if needed) of the large Hohmann retractors superiorly over the greater tuberosity to fully expose the rotator cuff (supraspinatus/infraspinatus). Visualization is key, as the infraspinatus determines the posterior portion of the anatomic cut of the humeral head. Then place a reverse Hohmann retractor medially and Browne deltoid retractor laterally. This retractor can be held by the scrub tech. Clearly identify the rotator cuff, as this will determine the anatomic cut. | **Figure 22**

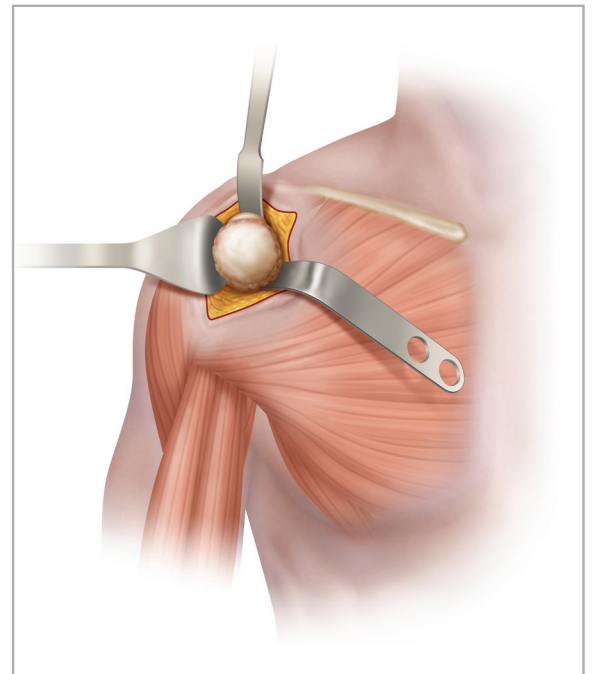


Figure 22
Retractor placement for humeral exposure

Outline the osteophytes with electrocautery. | **Figure 23A** Use a ½" straight osteotome, a mallet and a rongeur to remove the osteophytes. | **Figure 23B** To ensure you have correctly removed the osteophytes, the capsular reflection (fatty adipose) should be visible and removed with the rongeur. | **Figure 23C** Osteophyte removal is key in the identification of the true anatomic neck.

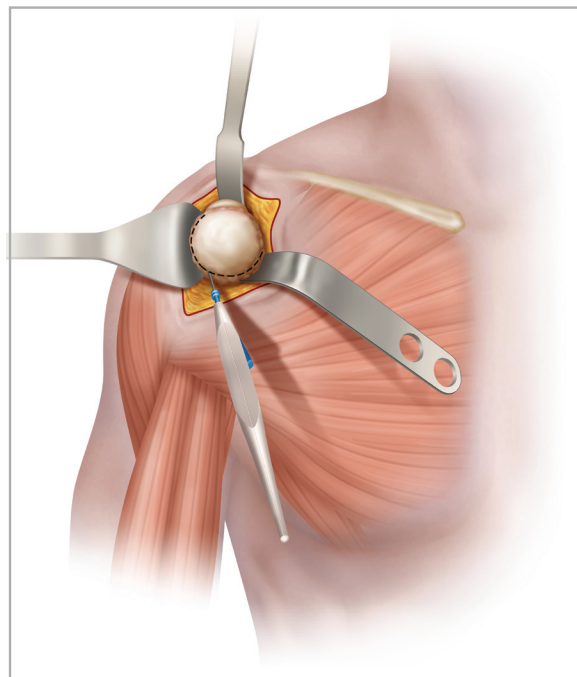


Figure 23A
Outline osteophytes

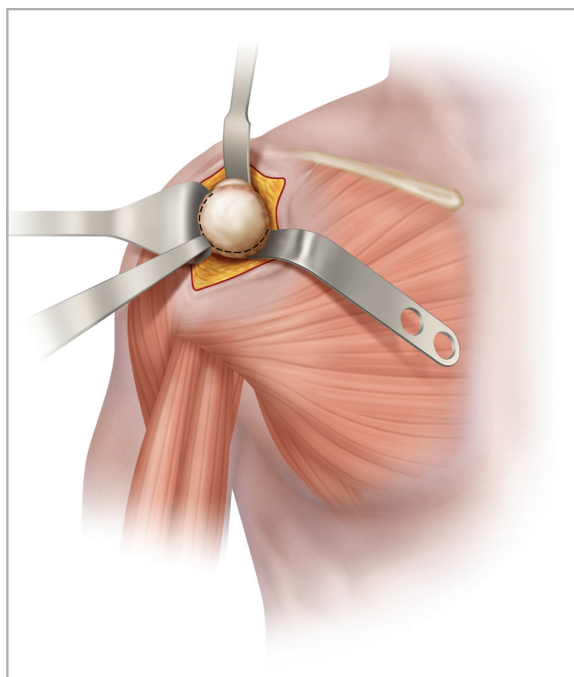


Figure 23B
Removal of humeral osteophytes

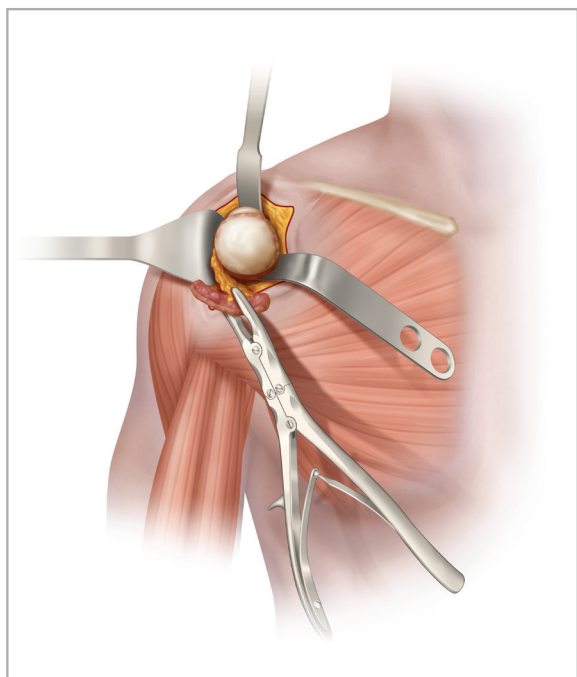


Figure 23C
Removal of humeral osteophytes

Humeral preparation

Use a saw to make the anatomic cut of the humeral head, being mindful of version and tilt. 5mm should remain between the cuff and the cut.

| **Figure 24A** If desired, an intramedullary cut guide may be introduced for guided resection of the humeral head. | **Figure 24B** Save the humeral head in case it is needed for bone grafting.

When preparing for an anatomic procedure, the initial size of the humeral head trial can be determined by placing the resected head onto one of the trial heads and determining which diameter and thickness most closely represents the resected head. | **Figure 25**

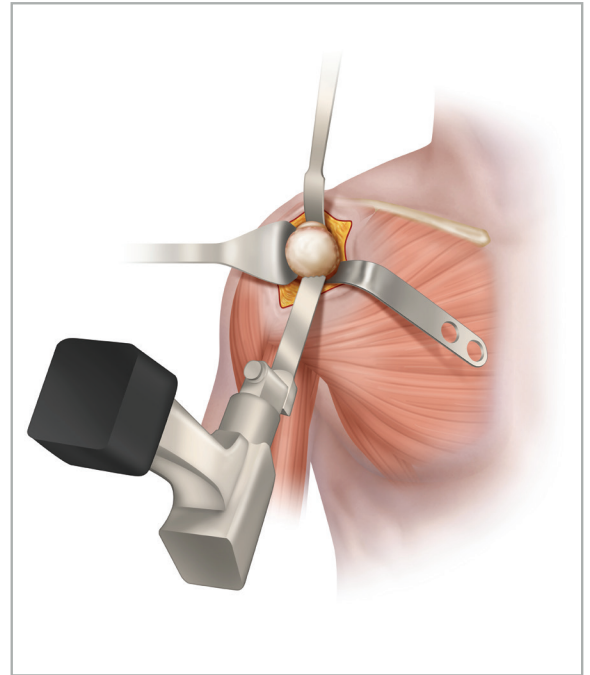


Figure 24A
Freehand resection of the humeral head

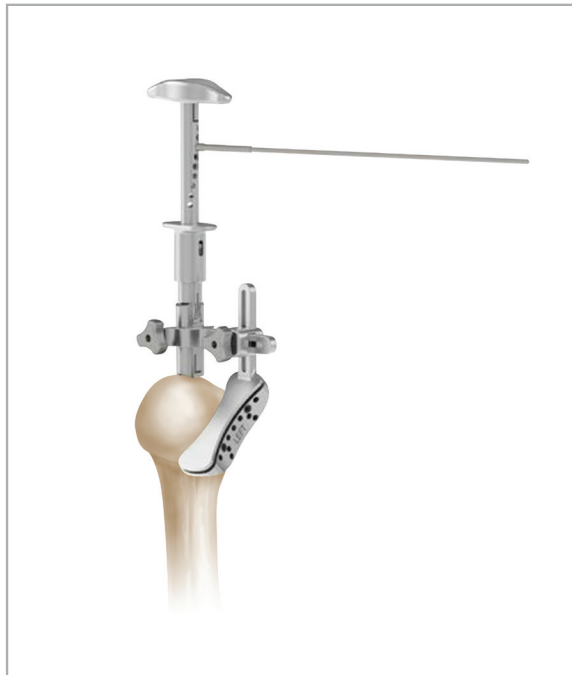

Figure 24B
Intramedullary humeral cut guide




Figure 25
Trial humeral head

Humeral instrumentation

Essential retractors:

- 1 large Hohmann
- 1 reverse Hohmann
- 1 Browne deltoid

At this point in the procedure, the large Hohmann retractor remains in place superiorly. The reverse Hohmann retractor is in place medially with the Browne deltoid retractor lateral. | **Figure 26**

The illustrations below depict an outline of the steps and instrumentation that will be utilized when preparing the humerus. | **Figures 27A and 27B**
For detailed surgical steps, please see the appropriate operative technique for the implant system being used.

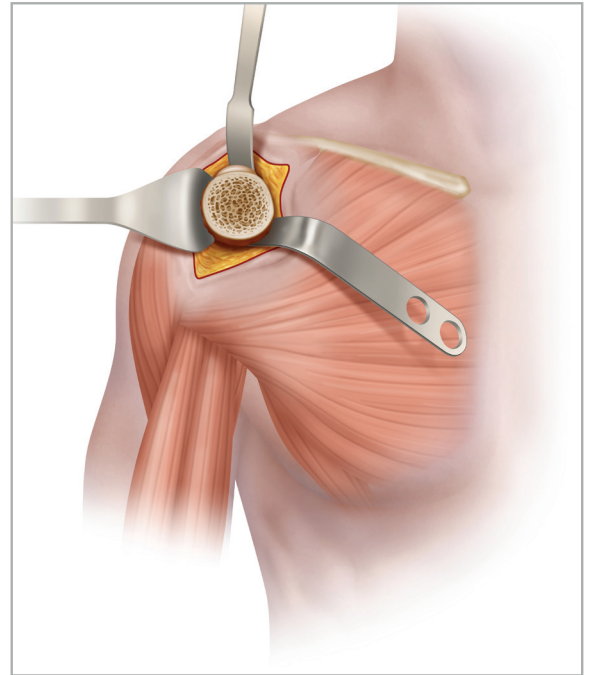


FIGURE 26

Retractor positioning for humeral exposure and preparation

Tornier Simpliciti anatomic humeral preparation steps

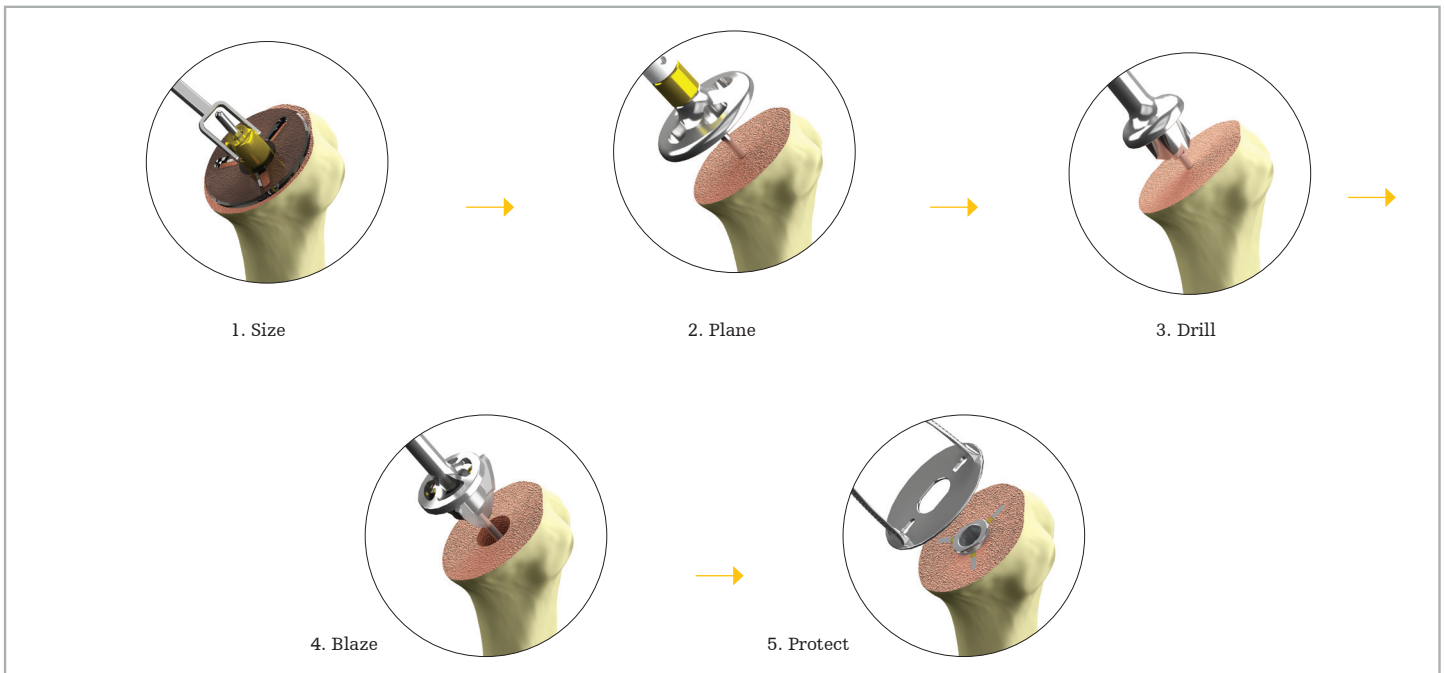


Figure 27A

Tornier Simpliciti Humeral Instrumentation progression

Humeral preparation

Tornier Flex Anatomic/Reverse Humeral preparation steps

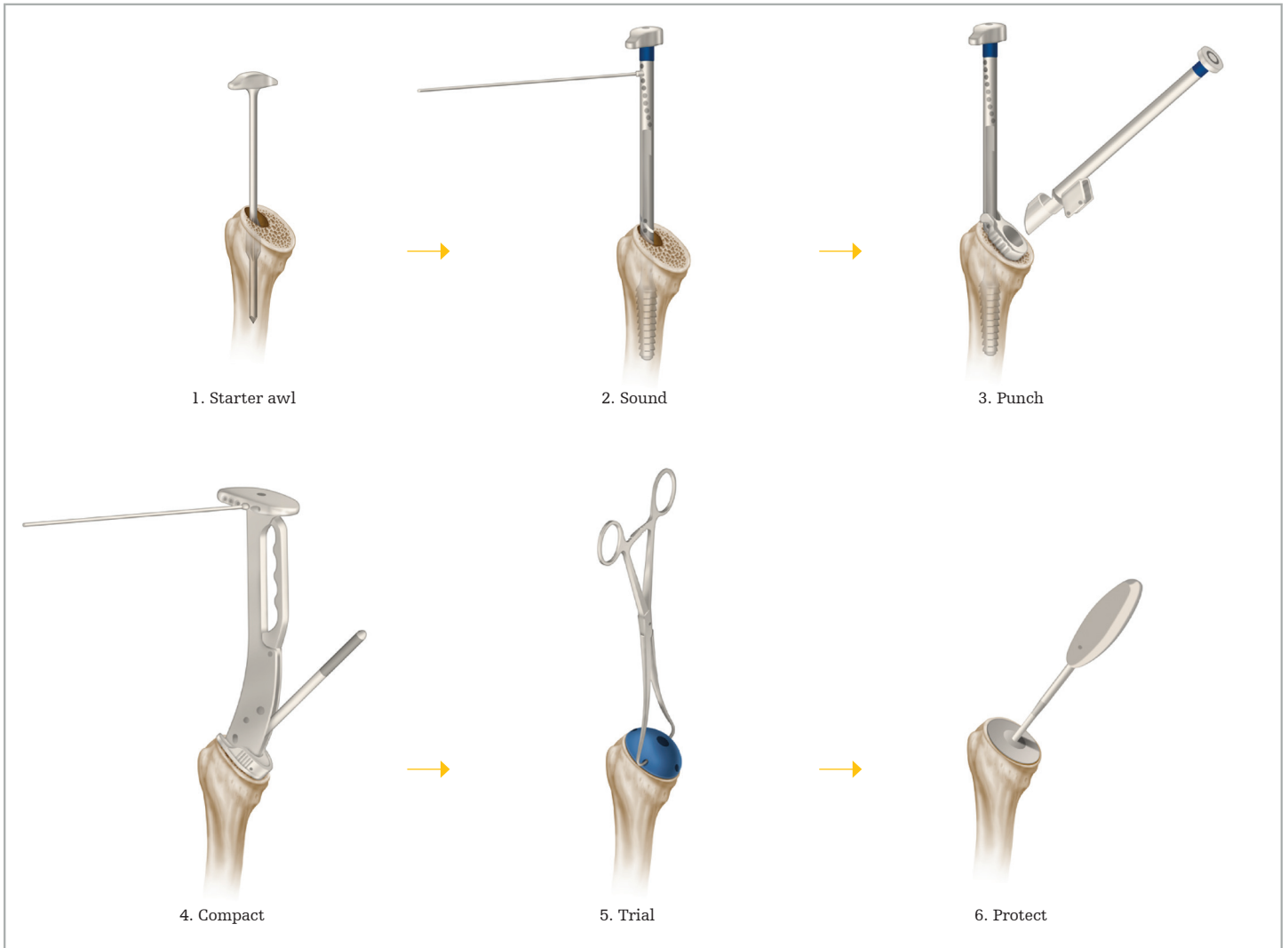


Figure 27B
Tornier Flex Humeral Instrumentation progression

Establish glenoid exposure

Coracohumeral and glenohumeral ligament releases

Essential retractors:

- 1 large Hohmann
- 1 Richardson
- 1 posterior retractor

To establish glenoid exposure, first place a Hohmann over the superior glenoid. Take care not to place the tip of the retractor too deep to avoid potential contact with suprascapular nerve. The posterior retractor is placed on the posterior glenoid to retract the resected humerus posteriorly. | **Figure 28** The posterior retractor is inserted by internally rotating the arm, positioning the tip on the posterior glenoid, then externally rotating the arm to retract the resected humerus posteriorly.

The following retractors can be used in place of the posterior retractor for posterior glenoid retraction: small fukuda, trillat, long narrow Darrach.

After the posterior retractor has been properly inserted, the Richardson is used to again retract the conjoined tendon medial. In the following steps, the hemostat and sutures in the subscapularis will be used to maneuver the subscapularis and identify the ligaments on the underside that will be released. To begin, locate and resect the coracohumeral ligament.

| **Figure 29** Next, locate the superior glenohumeral ligament (SGHL) and middle glenohumeral ligament (MGHL). Using a Ferris-Smith heavy forceps and curved Mayo scissors, release the SGHL and MGHL back to the level of the glenoid. | **Figure 30**

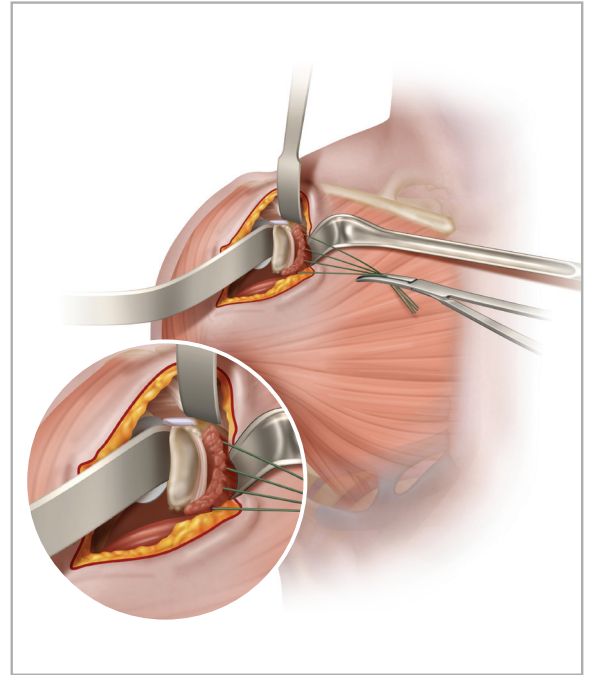


Figure 28
Positioning of posterior retractor

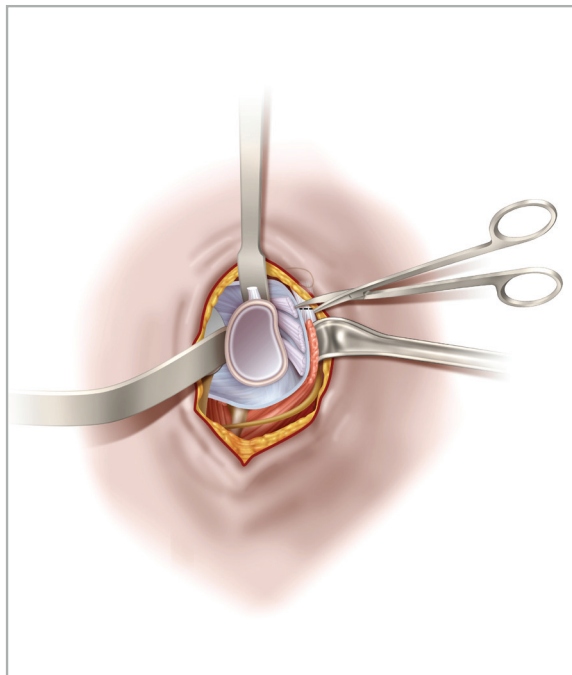


Figure 29
Coracohumeral ligament release

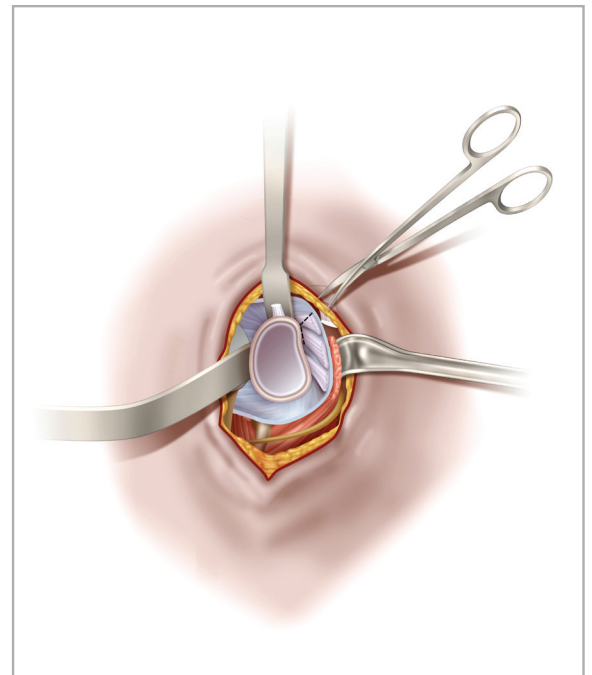


Figure 30
Release of SGHL and MGHL

Establish glenoid exposure

Prior to releasing the inferior glenohumeral ligament (IGHL), it is important to note that the axillary nerve lies anterior to the muscle belly of the subscapularis and then traverses posterior underneath the capsule below the inferior glenoid. The IGHL is located posteriorly to the subscapularis. When performing your release, ensure that there is muscular subscapularis covering the axillary nerve. As long as you avoid going anteriorly through the muscle, and are aware of its position inferior, the axillary nerve should remain protected.

Once you have ensured that the muscular subscapularis is protecting the axillary nerve anteriorly, you may proceed with resection of the IGHL. Start by placing the curved Mayo between the capsule (with confluent IGHL) and the posterior subscap muscle belly to create separation of the tissues.

| **Figure 31A** Next, complete the resection of the separated IGHL back to the level of the glenoid. | **Figure 31B**

Palpate the subscapularis recess to see if any loose bodies remain. Remove any identified loose bodies in the subscapularis recess.

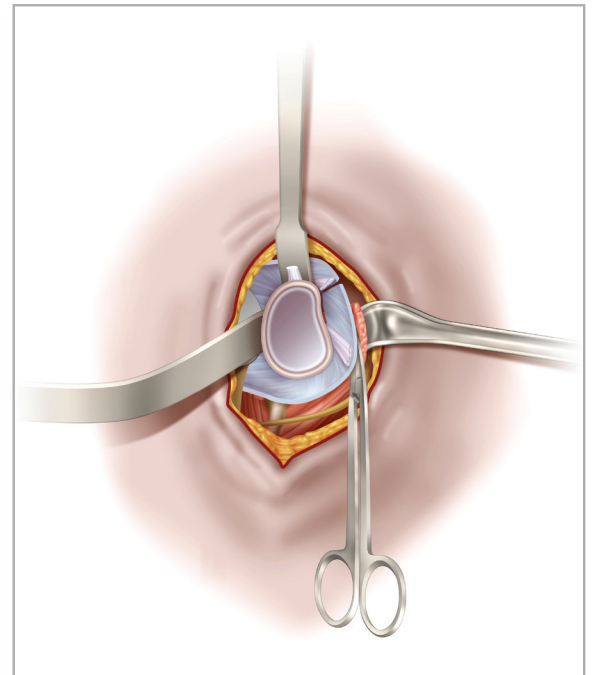


Figure 31A
Separation of IGHL/capsule from subscap

Release the hemostat from holding the subscapularis retention sutures. Pack the subscapularis tendon and the four suture strands into the subscapularis recess to protect the subscapularis as you continue with the procedure.

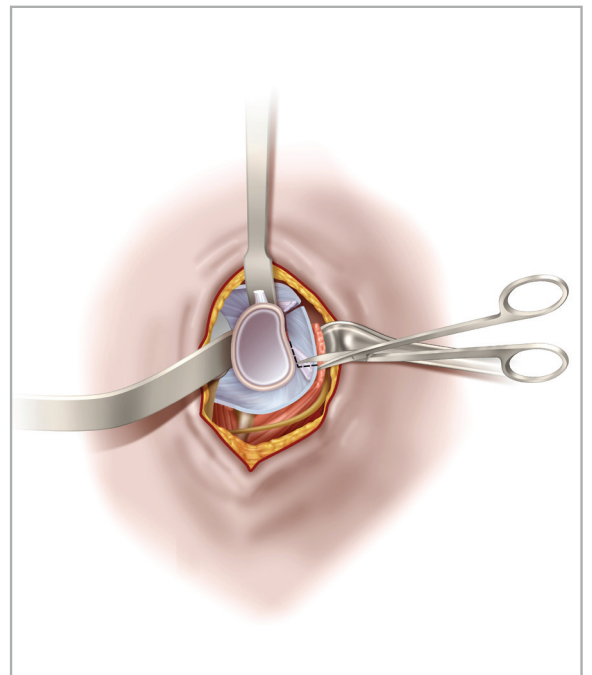


Figure 31B
Resection of IGHL

Essential retractors:

- 1 posterior retractor
- 1 narrow Kolbel
- 1 large Hohmann

The Richardson retractor is now removed from the conjoined tendon and the Kolbel retractor is placed on the anterior glenoid to provide visibility for glenoid exposure. | **Figures 32A and 32B** The scrub tech should only apply two finger light pressure to the Kolbel retractor. Placing excessive pressure on the Kolbel retractor will limit the ability of the posterior retractor to gain exposure posteriorly.

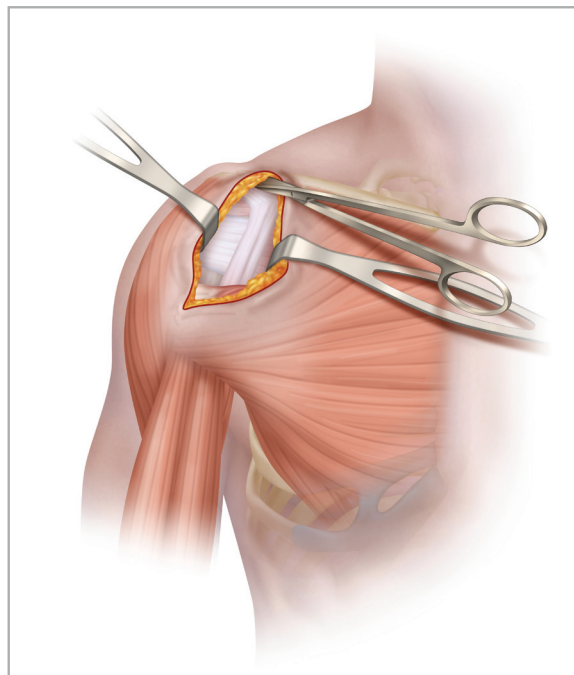


Figure 32A
Exposure during glenoid preparation

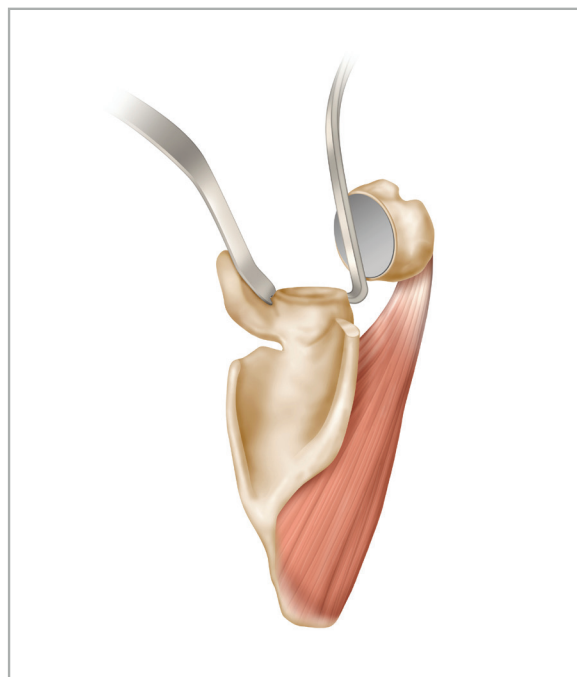


Figure 32B
Glenoid exposure using posterior retractor

Establish glenoid exposure

Anterior labrum release

Using Ferris-Smith forceps, grasp the remaining biceps stump. Use electrocautery to begin removing the anterior glenoid labrum.

| **Figure 33**

Inferior capsule release

The inferior capsule and labrum release will extend posterior to the 7 o'clock position for a right shoulder and to the 5 o'clock position for a left shoulder. | **Figure 34** The depth of the release (remaining right on the bone) will usually extend to the insertion of the long head of the triceps.

| **Figure 35** To check your release, use a Cobb elevator to tension the inferior capsule and soft tissue to confirm that enough inferior release has been achieved. The inferior glenoid capsular release is key in achieving adequate glenoid exposure.

Note: Be sure to remain directly on the bone/inferior rim of the glenoid and always be mindful of the axillary nerve.

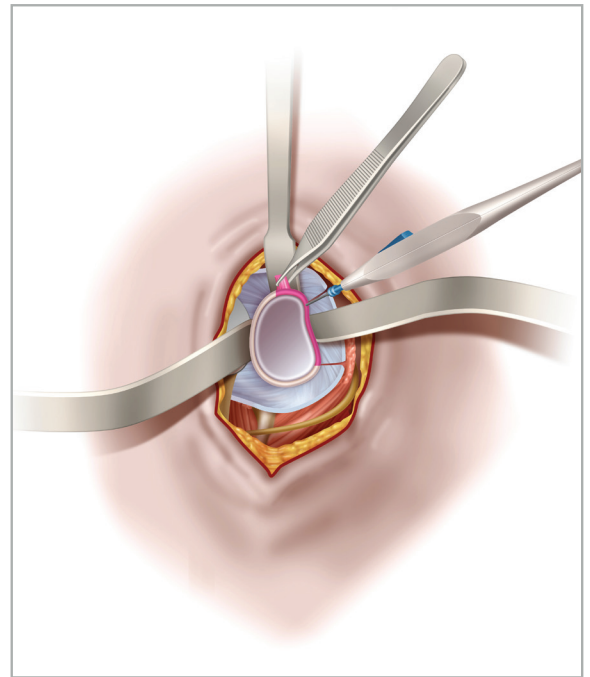


Figure 33
Resection of anterior glenoid labrum

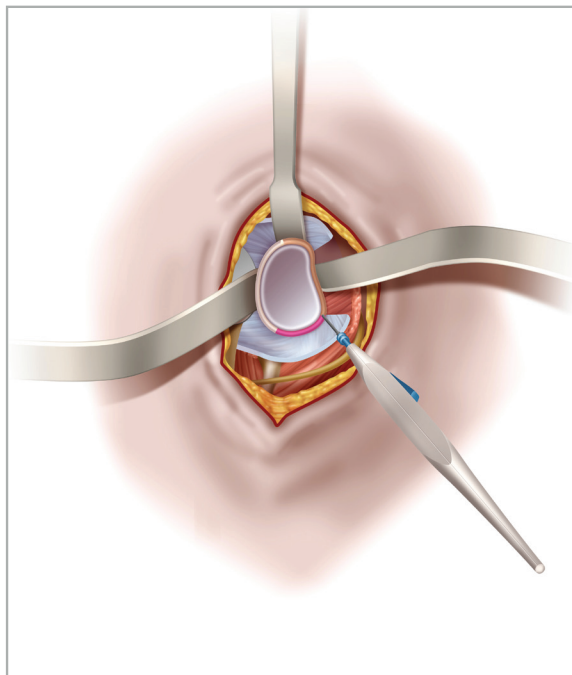


Figure 34
Inferior glenoid capsular release

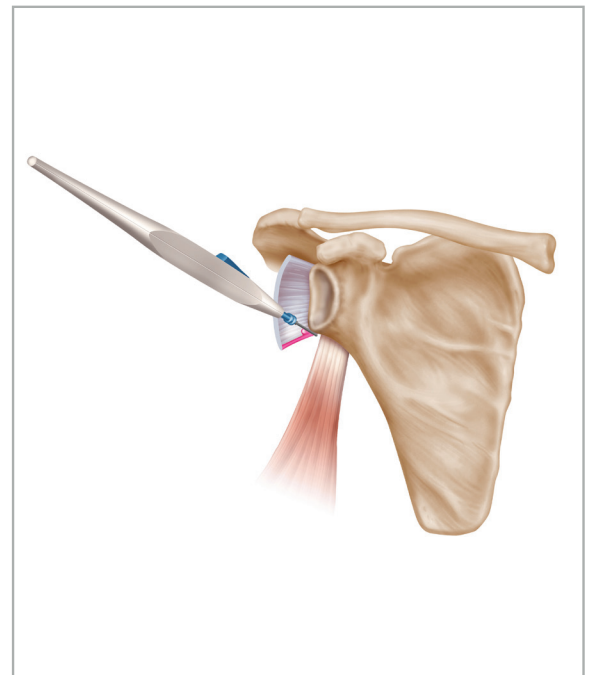


Figure 35
Inferior glenoid capsular release to
long head of triceps insertion

Posterior releases

When performing an anatomic shoulder replacement, use the Ferris-Smith forceps and electrocautery to remove the posterior labrum, leaving the posterior capsule intact. | **Figure 36** Proceed with removing any remaining residual superior labrum.

For a reverse shoulder, you may perform a complete posterior capsular release.

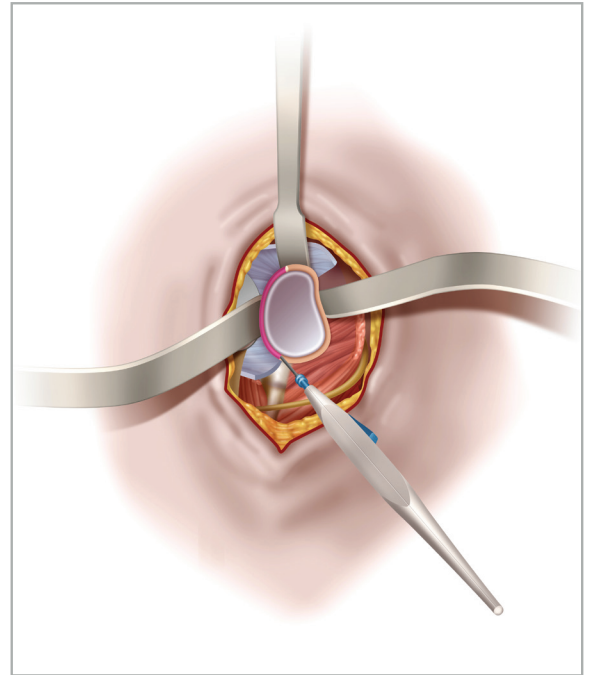


Figure 36
Posterior labrum removal

Glenoid instrumentation

Anatomic glenoid instrumentation

The following pages depict the surgical flow followed when using the cannulated technique for an anatomic glenoid. Although the cannulated technique is shown, instrumentation is available if a non-cannulated approach is preferred. For detailed steps, please see the appropriate operative technique for the implant system being used.

The posterior retractor is designed to create a pocket of space posteriorly to reduce contact between the retractor and reamer blade during reaming.

| **Figure 37** When removing the posterior retractor, angle the retractor parallel to the face of the glenoid to avoid catching the back edge of the glenoid implant upon removal. | **Figure 38**

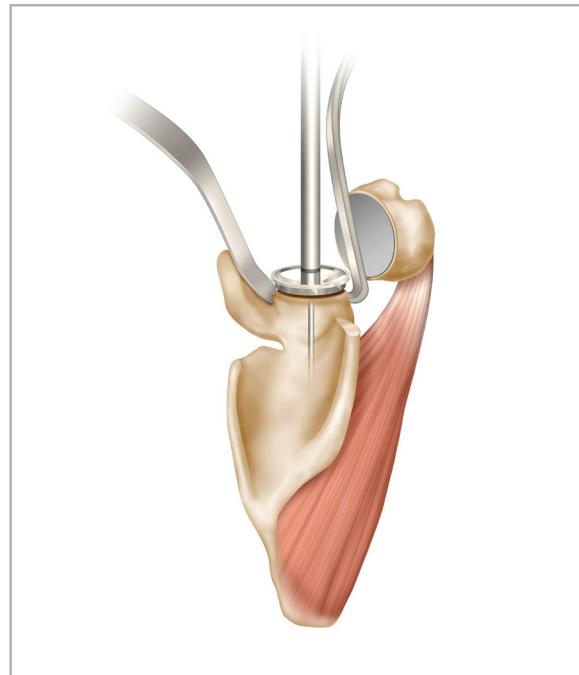


Figure 37
Exposure with posterior retractor

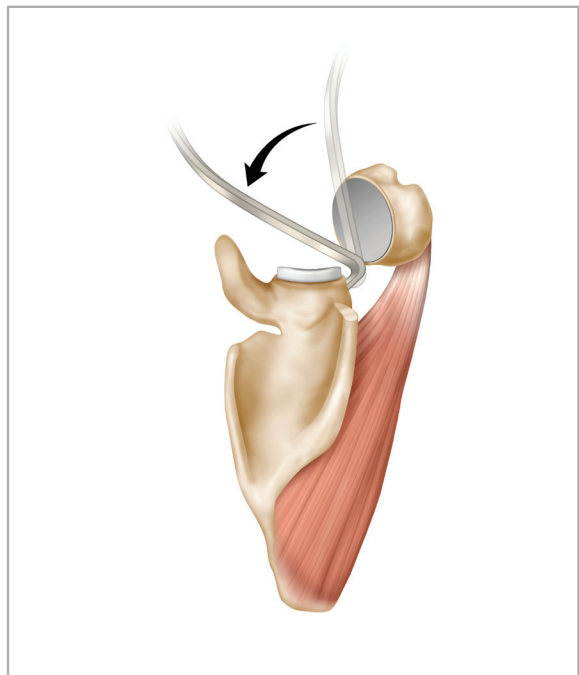
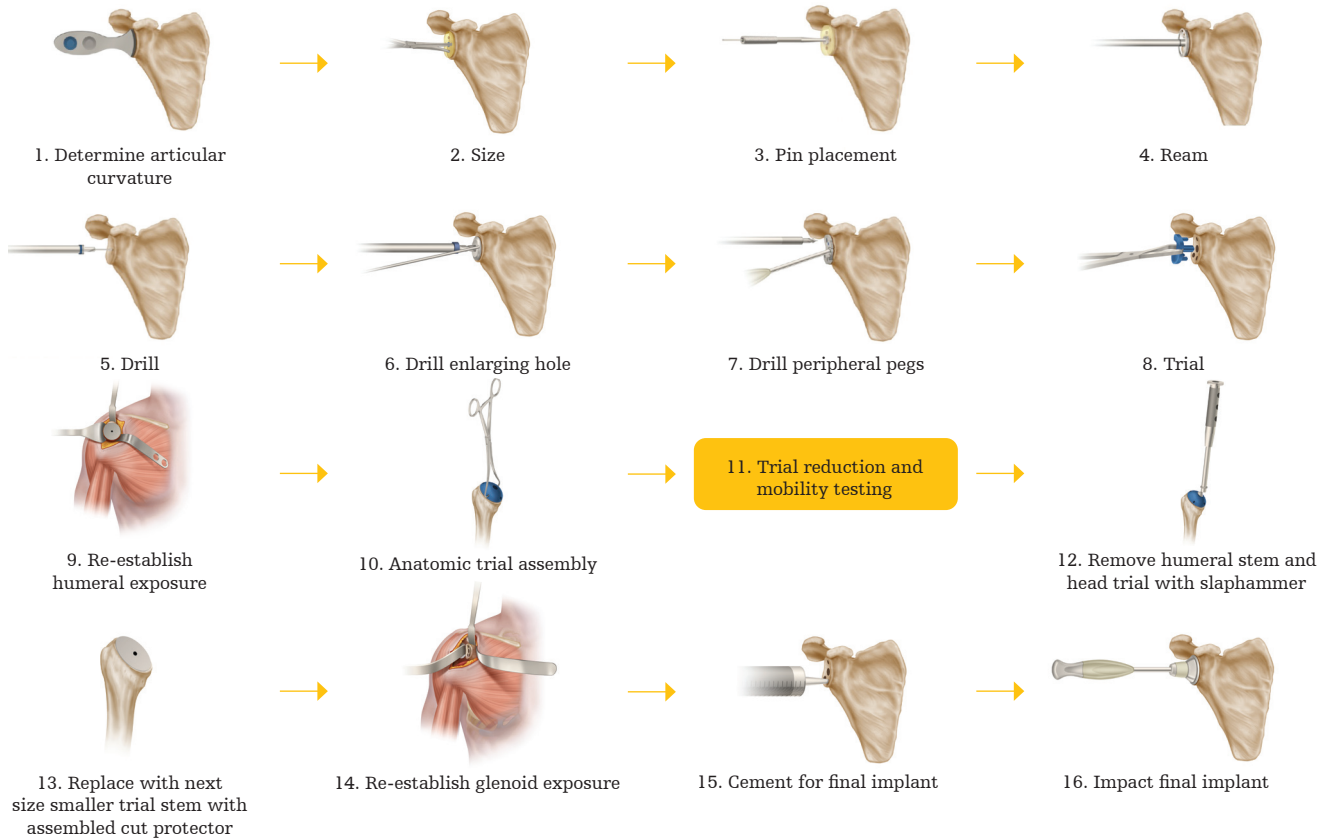


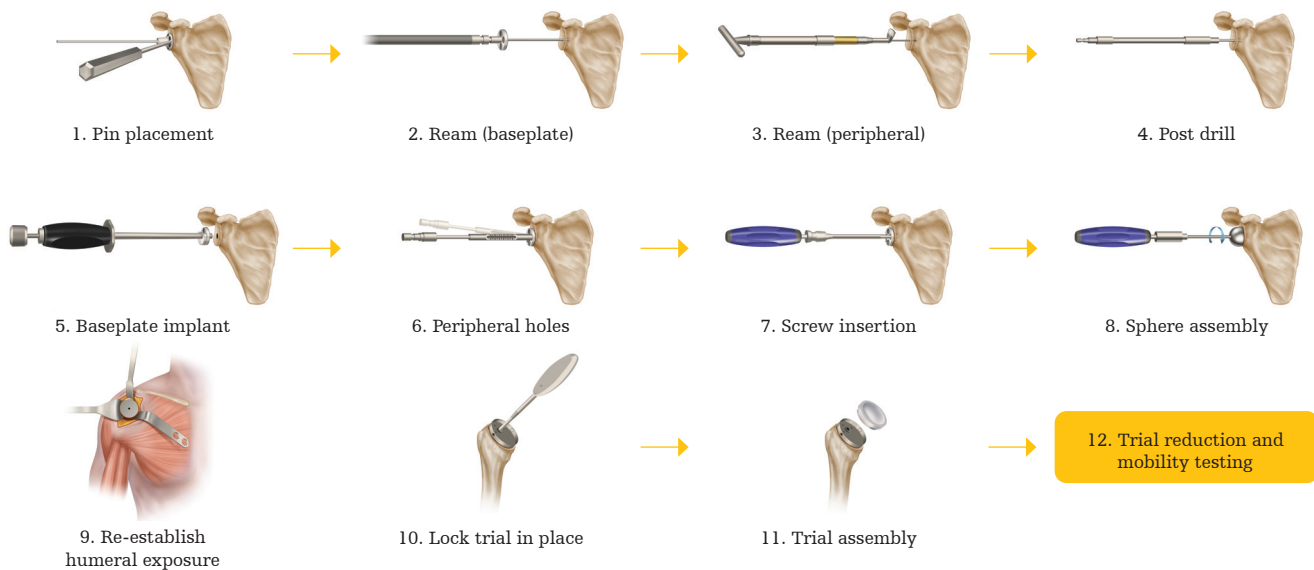
Figure 38
Removal of posterior retractor

Anatomic glenoid instrumentation



Reversed glenoid instrumentation

The following pages depict the surgical flow followed when using the cannulated technique for a reversed glenoid. Although the cannulated technique is shown, instrumentation is available if a non-cannulated approach is preferred. For detailed steps, please see the appropriate operative technique for the implant system being used.



Glenoid instrumentation

Final humeral implantation

Essential retractors:

- 1 large Hohmann
- 1 reverse Hohmann
- 1 Browne deltoid

Re-establish humeral exposure using the Hohmann, reverse Hohmann, and Browne deltoid retractors. | **Figure 39** While the final implants are being prepared, use 3 separate #2 non-absorbable, high tensile suture with a heavy needled driver to place 3 sutures in the subscapularis residual tendon on the humerus and into the humeral canal (for a transtendinous and transosseous subscapularis repair). The first suture will be placed first through the stump of the superior subscapularis laterally, then transosseously through the lesser tuberosity and finally out through the canal. | **Figure 40**

Repeat this step again, moving slightly more inferior each time. The final suture will be done through the inferior subscapularis. Use 3 different sized hemostats to differentiate the 3 sutures and make them easier to identify. Snap the superior suture with a large hemostat, the middle suture with a small hemostat and the inferior suture with a different sized hemostat. | **Figure 41** Upon completion of the sutures being placed, proceed to the implantation steps outlined in the surgical technique for the implant being utilized. | **Figure 42**

Next, perform the final implantation of the humeral implant followed by a check for proper stability and range of motion. Consult the appropriate operative technique for details on final implantation of the Tornier Flex and Tornier Simpliciti Shoulder System.

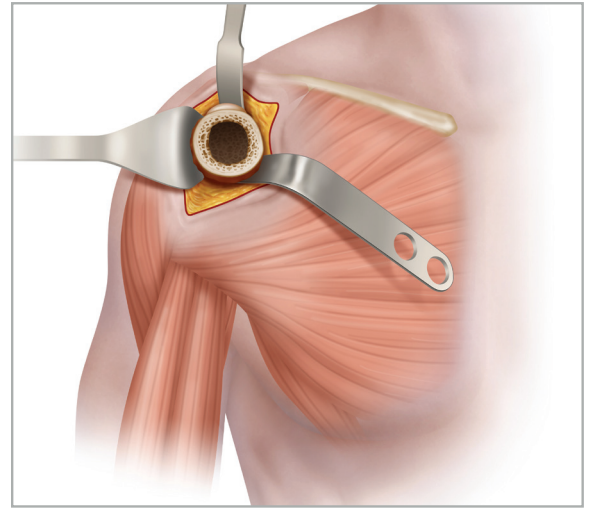


Figure 39
Establish glenoid exposure

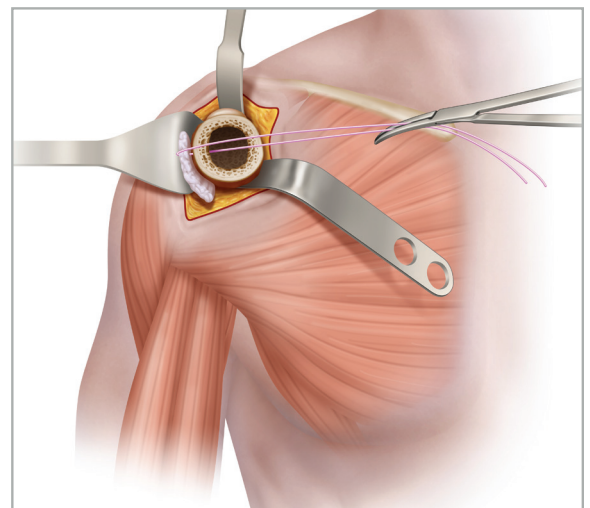


Figure 40
First suture placement for subscapularis repair

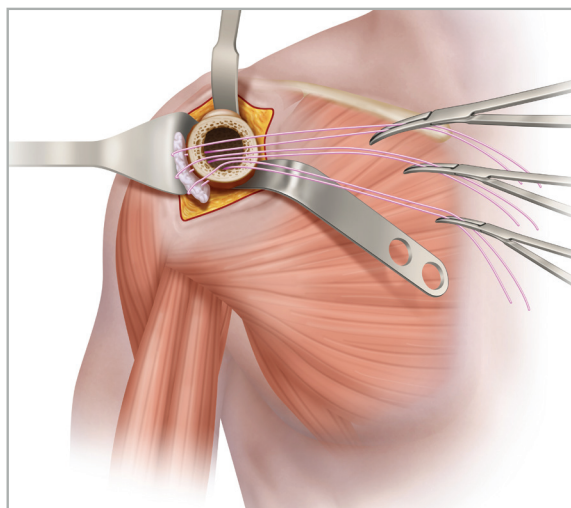


Figure 41
Location of three subscapularis repair sutures

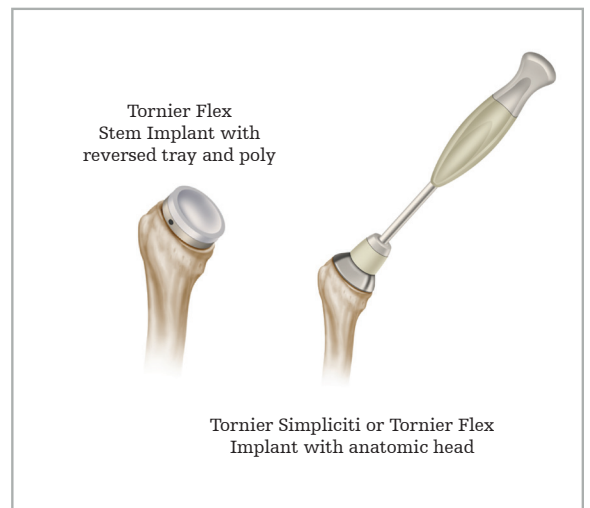


Figure 42
Final implementation steps

Reduction, subscapularis and rotator interval closure

Essential retractors:

- 1 Richardson
- 1 Army-Navy

Remove the humeral retractors. Reduce the humerus by placing an index finger between the humeral head and the anterior retractor to prevent any contact against the articular surface. | **Figure 43** After placing the implant, recheck the range of motion tests performed earlier with the trial components to confirm final range of motion and ensure the implants are free from tightness or impingement.

Place a Richardson retractor medially under the conjoined tendon. Place an Army-Navy retractor laterally to provide additional deltoid retraction to help with the identification of the rotator interval.

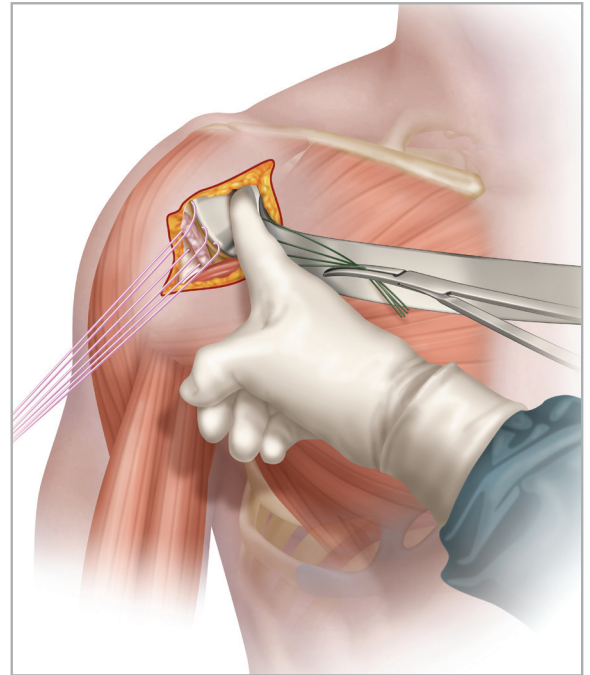


Figure 43
Reduction of final implants

Identify the tag sutures placed in the subscapularis earlier in the procedure and grasp the sutures with a Kocher clamp or hemostat, as this will give you control of the subscapularis for repair. | **Figure 44**

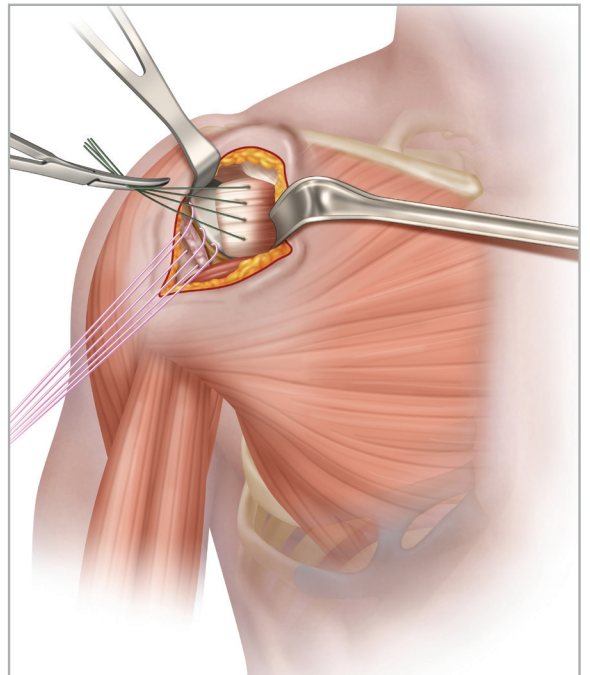


Figure 44
Retractor placement for subscapularis repair and grasping of subscapularis tendon

Reduction, subscapularis and rotator interval closure

Take the heavy forceps and grasp the subscapularis. Pass the superior suture from the subscapularis tendon on the humeral side through the subscapularis. | **Figure 45**

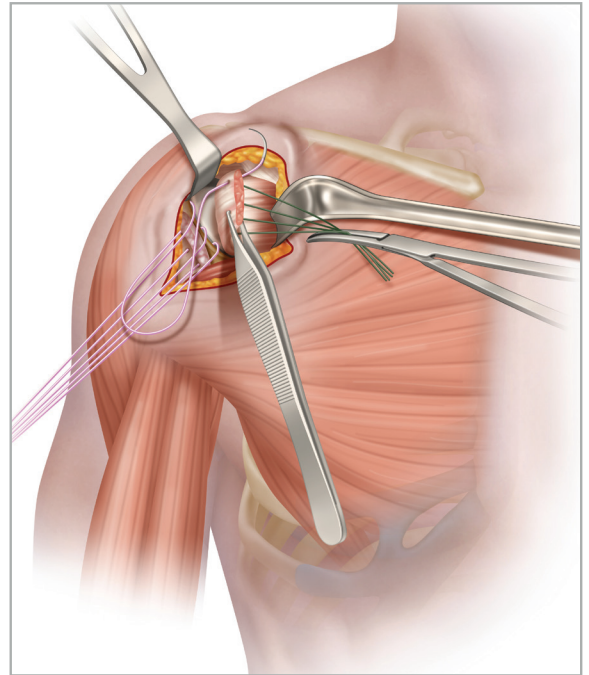


Figure 45
Superior humeral subscapularis tendon suture passed through superior subscapularis tendon

The suture is then passed back through the subscapularis stump, laterally on the tuberosity. | **Figure 46**

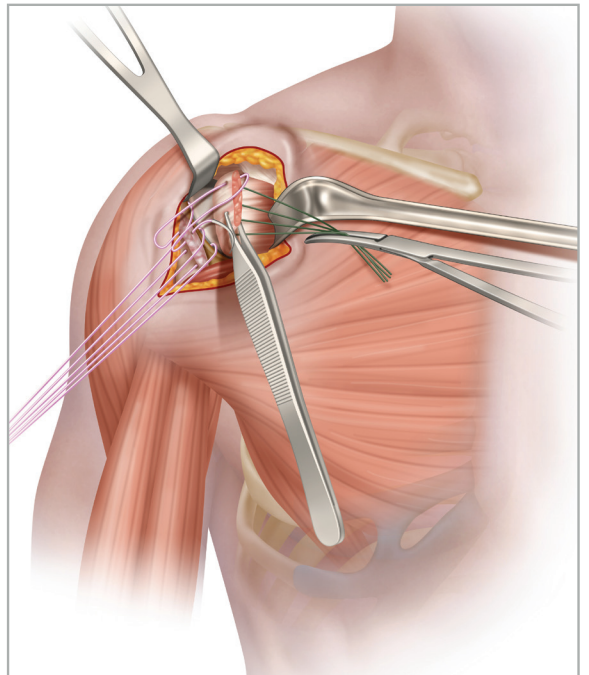


Figure 46
Suture passage back through humeral subscapularis tendon

Then the suture is again passed back through the subscapularis tendon a second time for a horizontal mattress suture configuration. | **Figure 47**
The idea is to have both transtendinous and transosseous repair of the subscapularis.

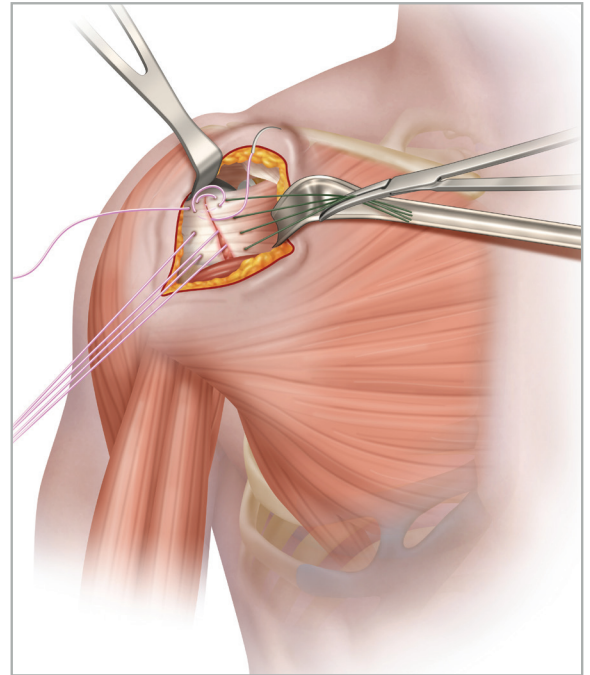


Figure 47
Second suture passage back through subscapularis tendon

Finally, tie the suture down with appropriate surgical knots. Upon completion of the superior subscapularis stitch, remove the tag sutures from the subscapularis tendon. | **Figure 48**

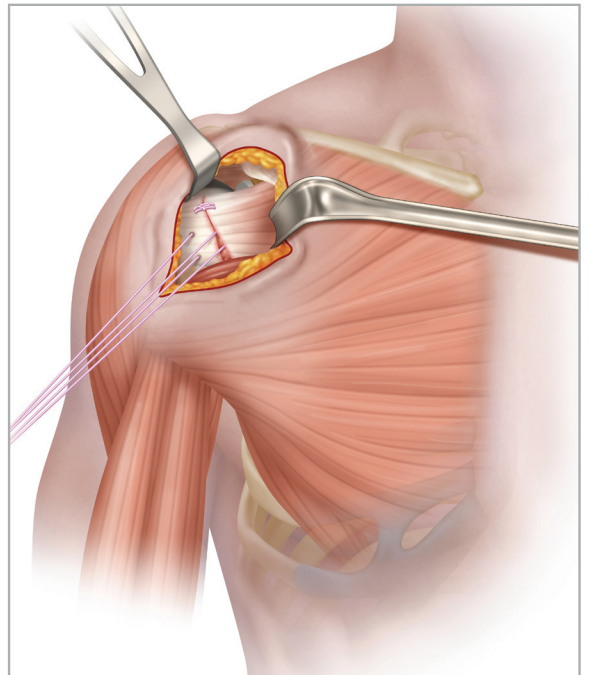


Figure 48
Tie superior subscapularis suture and remove tag sutures

Reduction, subscapularis and rotator interval closure

Next, repair the rotator interval by placing a single #2 non-absorbable suture in a figure of eight fashion in the rotator interval tissue superiorly between the subscapularis and the supraspinatus tendon. | **Figure 49**
The arm should be in slight external rotation while closing the rotator interval to preserve external rotation postoperatively.

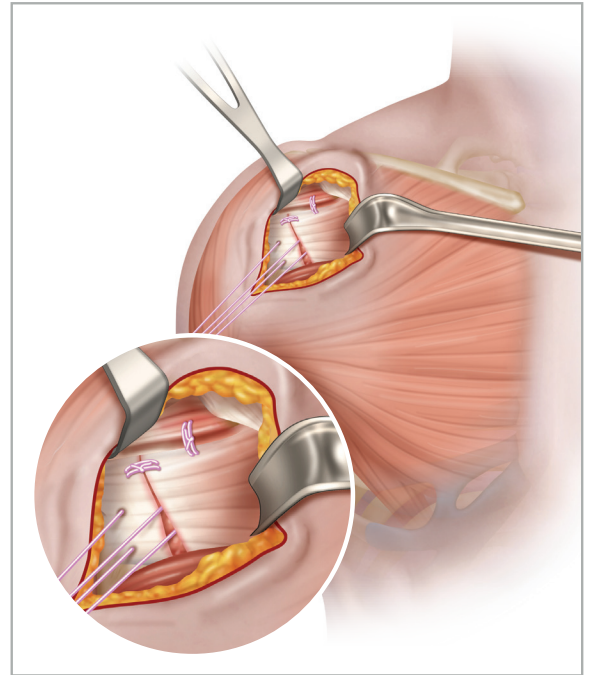


Figure 49
Repair of the rotator interval

Finally, the medial and inferior subscapularis stitches are each placed following the same method as the superior subscapularis stitch. Start by passing the suture from the subscapularis tendon on the humeral side through the subscapularis. The suture is then passed back through the subscapularis stump and again back through the subscapularis tendon a second time. | **Figure 50**

Additional fixation of the subscapularis can be performed using #1 vicryl absorbable suture on a tapered needle to avoid cutting out the transosseous sutures.

Finally, remove all remaining retractors. Ensure proper elevation over the head and external rotation.

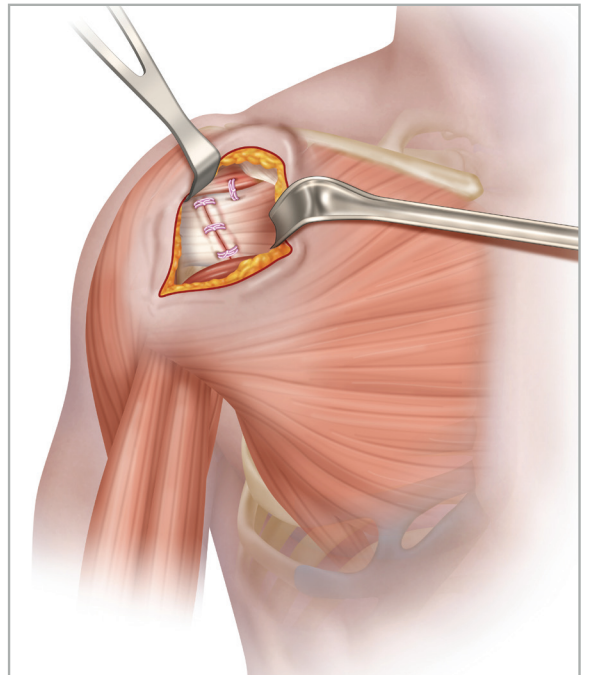


Figure 50
Final subscapularis repair

Pectoralis and deltopectoral interval closure

At this time the deltopectoral interval is closed. | **Figure 51**

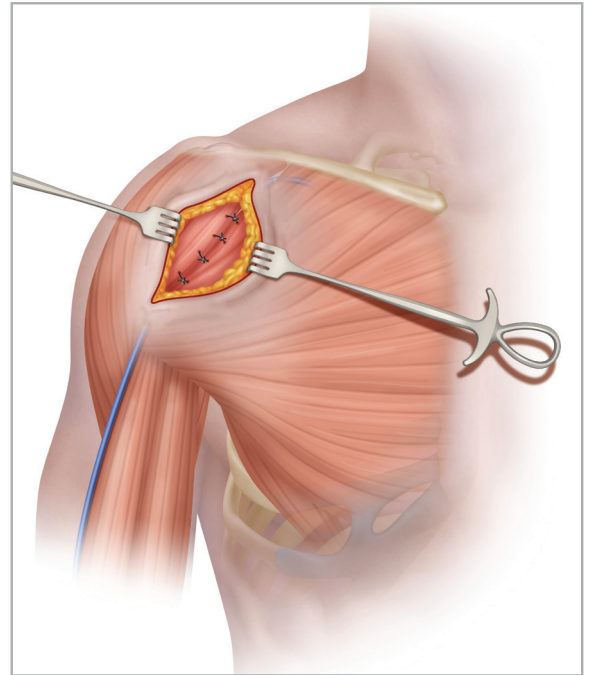


Figure 51
Closure of the deltopectoral interval

Wound closure

Copiously irrigate the wound.

Close the wound in layers, using 0 vicryl, 2-0 vicryl and 3-0 PDS. | **Figures 52A, 52B, 52C, and 52D**

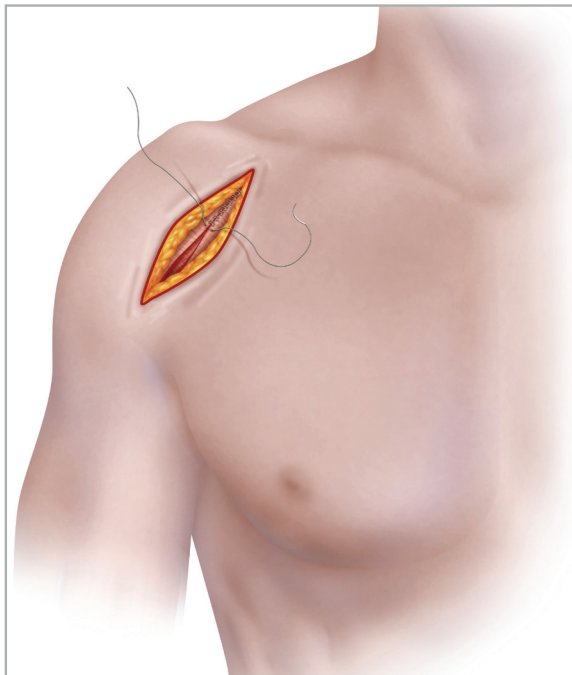


Figure 52A

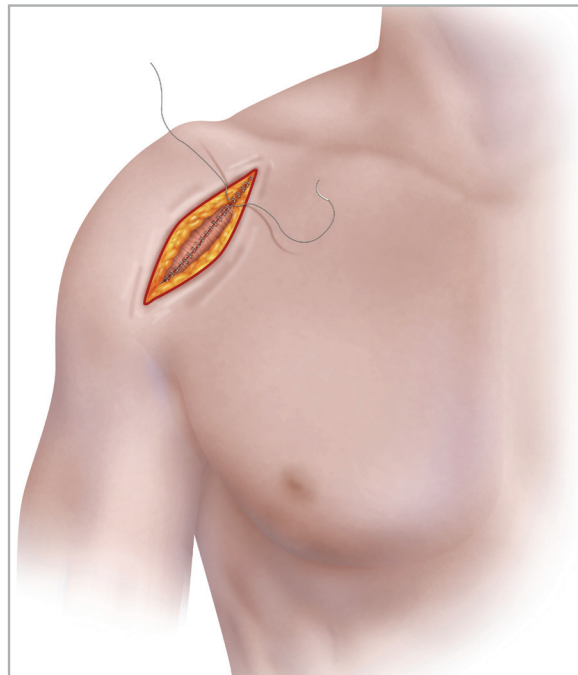


Figure 52B

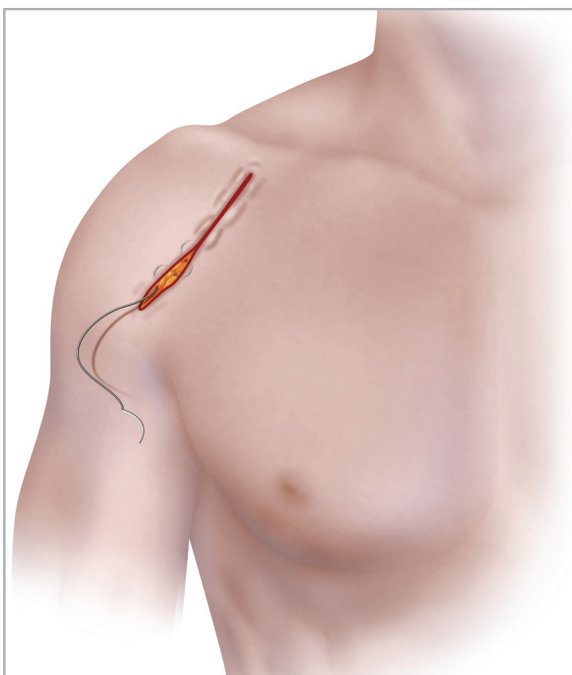


Figure 52C

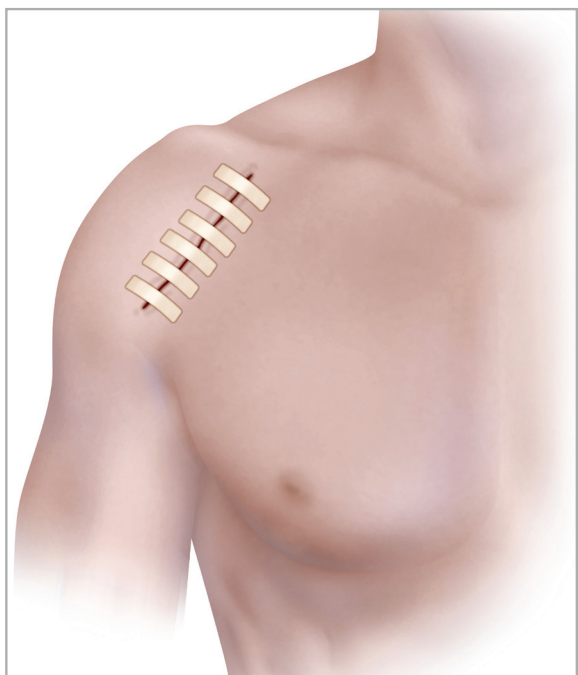




Figure 52D

System components

Standardized support instrumentation

Below is an overview of the instrumentation utilized throughout the technique that will be provided to your OR to ensure the team has the necessary equipment for every case.

<p>Long skin rake</p>  <p>MWH100 Qty: 2</p>	<p>Adson-cerebellar</p>  <p>MWH101 Qty: 2</p>	<p>Army-Navy retractor (set)</p>  <p>MWH102</p>
<p>Large Hohmann</p>  <p>MWH103</p>	<p>Richardson</p>  <p>MWH104</p>	<p>Grooved trillat</p>  <p>MWH105</p>
<p>Narrow Kolbel</p>  <p>MWH108</p>	<p>Reverse Hohmann</p>  <p>MWH111</p>	<p>Bone hook</p>  <p>MWH112</p>
<p>Posterior retractor</p>  <p>MWH623</p>	<p>Browne deltoid</p>  <p>MWH114</p>	<p>Double pointed Hohmann</p>  <p>MWH106</p>
<p>Long narrow Darrach</p>  <p>MWH107</p>	<p>Wide Kolbel</p>  <p>MWH109</p>	<p>Laminar spreader</p>  <p>MWH110</p>
<p>Prosthesis reducer</p>  <p>MWH113</p>	<p>Small fukuda</p>  <p>9000379</p>	<p>Aesculap tray</p>  <p>Base: YRAD105 Upper tray: YRAD1051 Lower tray: YRAD1052 Lid: YRAD1053 Tag: YRAT105</p>

Instrument ordering information

Description	Qty per pkg	Catalog no.
Retractor skin rake	1	MWH100
Retractor Adson cerebellar	1	MWH101
Retractor Army-Navy	2	MWH102
Retractor large Hohmann	1	MWH103
Retractor Richardson	1	MWH104
Retractor trillat grooved	1	MWH105
Retractor Hohmann double pointed	1	MWH106
Retractor Darrach long narrow	1	MWH107
Retractor Kolbel narrow	1	MWH108
Retractor Kolbel wide	1	MWH109
Retractor laminar spreader	1	MWH110
Retractor Hohmann reversed	1	MWH111
Retractor bone hook sharp	1	MWH112
Retractor prosthesis reducer	1	MWH113
Retractor Browne deltoid	1	MWH114
Posterior retractor	1	MWH623
Small fukuda	1	9000379
Outer case - shoulder retractor system base	1	YRAD105
Outer case - shoulder retractor system lid	1	YRAD1053
Upper tray - shoulder retractor system	1	YRAD1051
Lower tray shoulder retractor system	1	YRAD1052
Base tag	1	YRAT105

This document is intended solely for the use of healthcare professionals. A surgeon must always rely on his or her own professional clinical judgment when deciding whether to use a particular product when treating a particular patient. Stryker does not dispense medical advice and recommends that surgeons be trained in the use of any particular product before using it in surgery.

The information presented is intended to demonstrate a Stryker product. A surgeon must always refer to the package insert, product label and/or instructions for use, including the instructions for cleaning and sterilization (if applicable), before using any Stryker product. Products may not be available in all markets because product availability is subject to the regulatory and/or medical practices in individual markets. Please contact your Stryker representative if you have questions about the availability of Stryker products in your area.

The instructions for use, operative techniques, cleaning instructions, patient information leaflets and other associated labeling may be requested online at ifu.stryker.com or wright.com. If saving the instructions for use, operative techniques, cleaning instructions from the above mentioned websites, please make sure you always have the most up to date version prior to use.

Stryker Corporation or its divisions or other corporate affiliated entities own, use or have applied for the following trademarks or service marks: Simpliciti, Stryker, Tornier. All other trademarks are trademarks of their respective owners or holders.

Content ID: AP-015238B 01-Dec-2021

Copyright © 2021 Stryker

Manufacturer:

Tornier, Inc.
10801 Nesbitt Avenue South
Bloomington, MN 55437
t: 888 867 6437
t: 952 426 7600

stryker.com