

The Clavicle Hook Plate – A Literature Review

C. Doppmann BSc¹, I. Schaad, MSc², M.D. McKee, MD³, S. Brianza, PhD⁴

¹ Intern Biomechanics, Stryker Trauma & Extremities, Selzach, Switzerland

² Project Engineer Biomechanics, Stryker Trauma & Extremities, Selzach, Switzerland

³ Division of Orthopaedic Surgery, St. Michael's Hospital, University of Toronto, Toronto, Ontario, Canada

⁴ Manager R&D Biomechanics, Stryker Trauma & Extremities, Selzach, Switzerland

Abstract

Introduction: Treatment of distal clavicle fractures and/or acromio-clavicular (AC) joint dislocations continue to be a challenging problem. The aim of this study was to conduct a literature review on clavicle hook plates to assess the complications which may occur with hook plating, when the hook plate should be removed, and what is important to obtain good results in these cases. **Material & Method:** A systematic literature search was conducted in PubMed. Articles published between 2010 and 2014 describing the use of clavicle hook plates were included in this review. **Results:** Eleven articles matching the selection criteria were identified. Only two of these articles treated AC joint injuries, the remaining articles studied distal clavicle fractures. **Discussion & Conclusion:** Good results have been achieved when treating Neer Type II distal clavicle fractures and AC joint injuries with clavicle hook plates. Relatively high union rates and good shoulder performance post-operatively have been achieved compared to other treatment methods. However, the reported complication rates are relatively high. The most common complications include impingement in motion, subacromial osteolysis, pain, and plate migration. Nonetheless, many symptoms seem to resolve after plate removal. A good surgical technique, as well as proper choice of hook depth, and plate placement is important. To further reduce the risk of complications, it is recommended to use a plate which matches the patient's anatomy as closely as possible. Further studies are to be conducted to confirm the benefits of anatomically designed hook plates.

1. Introduction

The Stryker portfolio is constantly expanded by new implants. To most comprehensively meet market demands, the voice of the customer is collected and case studies are reviewed early in the development process. This insight together with the Stryker SOMA database (a diverse collection of CT scans), contributes to the design of new implants.

The newest example of this process is the Stryker VariAx Clavicle Hook Plate indicated for distal clavicle fractures and acromio-clavicular (AC) joint dislocations (Figure 1).

Hook plates are designed to allow physiological AC joint range of motion, while stabilizing the

clavicle itself, hence minimizing movement of the fracture fragments [1].

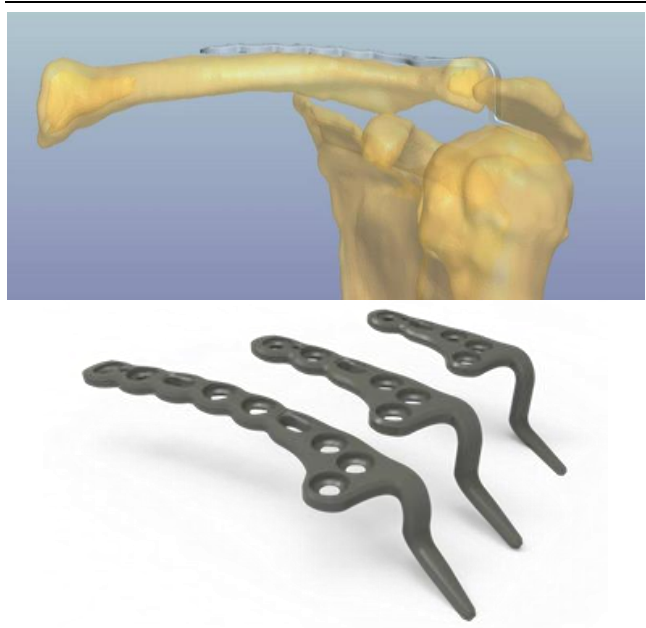


Figure 1: SOMA designed Stryker VariAx Clavicle Hook Plate

Due to the geometry of the plate, early physiological range of motion may be well tolerated, which may lead to better functional outcomes. In addition the early physiological range of motion may allow the patient to perform daily activities soon after surgery [2].

A literature review was conducted to determine why an anatomical plate shape may be of importance when using hook plates, which type of complications may occur, and the optimal timing of plate removal.

2. Material & Method

A systematic literature search was performed in PubMed with the key words *clavicle hook* and *clavicle hook plate*. Only articles written in English and published recently, from 2010 to 2014, were included. The resulting titles and abstracts were screened to fit the selection criteria. Studies dealing with midshaft or medial clavicle fractures and case studies were excluded from this review. In addition, the references of all selected papers were screened for further pertinent articles.

Meta-data was extracted from each paper and relative points were highlighted. If an article described several treatment methods, the meta-data was only included if it could be directly related to hook plates. The studies were graded according to the *Oxford Centre for Evidence-Based Medicine* (OCEBM) levels of evidence [3]. All this information was then summarized in Table 2.

3. Results

A total of eleven papers were included in this literature review (Table 2). Only two studies treated acute AC joint injuries, whereas the other papers concentrated on distal clavicle fractures. Four (5) retrospective case series and five (5) case control

studies (1 randomized, 4 retrospective) were included in this study.

Of the publications identified, eight used the Synthes 3.5mm LCP Clavicle Hook Plate, one the Litos tifix® AC-hook Plate and two did not report the plate type used. These similar hook plates have primarily been used for displaced lateral-third clavicle fractures (Neer Type II) and for AC ligament injuries (Rockwood grade III-VI). Two papers reported high complication rates [4] [5], whereas others had satisfactory results with good shoulder performance post-operatively [2] [6] [7] [8].

Distal clavicle fractures compose 20% [9] of all clavicle fractures and various treatment methods exist. Therefore, information was considered carefully according to the level of evidence and the number of cases. There was no standard way to assess the severity of complications, resulting in some studies having much higher complication rates than others, while using the same treatment methods. Consequently, the validity of our observations is limited.

Wu et al. [7] as well as Kienast et al. [10] found that the hook plate allowed early functional therapy which was shown to facilitate an accelerated healing process. This shortened the time to removal and helped to minimize limitations in the post-operative shoulder range of motion.

Anatomical Plate Shape

The authors report that adjusting the plate to the anatomy of the patient resulted in lower complication rates and better final results [2] [7]. Further, it was found that contouring the plate to fit the anatomy correlated with higher Constant-Murley scores [7].

Tan et al. [6] pointed out that the hook induced a high stress on the acromion and subacromial structures which led to inflammation and impingement.

Consequently, the shape of the hook may be critical in regard of the risk of such complications.

Complications

In the analyzed publications the clavicle hook plate was associated with high complication rates (Table 1), and recommendations are made on how to minimize the potential problems.

Table 1: List of complications reported for clavicle hook plates

Type of Complication	No. of cases	Sources
Pain	27	[2] [6]
Subacromial osteolysis / erosion	24	[2] [4] [11] [12]
Fluid accumulation / Seroma	14	[10] [11]
Periprosthetic fracture	13	[5] [7] [10] [13]
Infection	12	[2] [5] [6] [8] [10] [13]
Re-dislocation of the AC joint after plate removal	9	[8] [10]
Plate migration / Hook migration	5	[4]
Hardware failure	5	[5] [10]
Impingement in motion	4	[2]
Implant loosening	3	[4]
Radiographic AC joint degeneration	3	[4]
Non-union	2	[2] [4]
Plate malpositioned /dislocation of hook	2	[7] [8]
Bone infection / Osteitis	2	[10]
Rotator cuff tear or lesions	1	[4]
Radiographic AC joint superior subluxation	1	[4]
Supraspinatus bursal-side degenerative changes	1	[4]
Abnormal subacromial bursal “bunching” with arm abduction	1	[4]
AC joint arthrosis	1	[2]

Complication rates were highest while the hook plate was in place, and were reduced or disappeared completely after plate removal [2] [4] [6] [10] [12]. Impingements in motion, pain and subacromial erosion were shown to improve significantly once the plate was explanted [4] [6].

Bhatia et al. [4] and Tan et al. [6] suggested that the hook plate may predispose subacromial structures and the undersurface of the acromion to inflammation and impingement, which may result in shoulder pain and functional limitations. Wu et al. [7] and Chen et al. [12] similarly concluded that the hook may cause erosion of the acromion, especially a point loading from a poorly fitted plate. Further,

they found that even a low-energy injury may re-fracture the clavicle medially to the plate [7].

Bhatia et al. [4] demonstrated the safety of the hook plate in regard to the rotator cuff and the subacromial bursa with ultrasonographic evaluations. Tiren et al. [2] observed subacromial osteolysis, which resolved after plate removal. They emphasized that the long-term clinical outcomes were satisfactory after implant removal. Additionally, Tiren et al. [2] found no relation between short term complications and mid-term functional results after plate removal.

Klein et al. [5] studied the importance of the time to surgery with the hook plate. They concluded that the longer the time from injury to surgery, the higher the risk of complications. This highlights the importance of treating unstable distal clavicle fractures as soon as possible.

In general, high union rates were achieved with the clavicle hook plate [6] [7] [11] [12]. Some articles measured the time to union. They found that fracture union on average occurred approximately after three months [6] [11] [13]. However, the time to union was extremely variable and should always be verified individually.

Good surgical technique is very important for placement of the clavicle hook plate. It has been reported that poorly placed hook plates may lead to hook migration [4]. Further, the plate may not function correctly if the hook is not placed correctly under the acromion, which may delay the healing process [7] [10]. In two publications it was reported that a malpositioned hook contributed to non-union [2] [7]. The authors concluded that hook placement was very critical. To reduce complications, the position of the plate should be verified with fluoroscopy and/or arthroscopy during surgery [2].

Plate Removal

Most sources recommend routine hook plate explant after bony union or joint healing. The removal of the plate is recommended to reduce the risk of complications such as rotator cuff tears or acromial osteolysis [7] [8]. In addition, in most cases removing the plate resulted in a reduction of some of the existing complications such as impingements, pain or osteolysis [4] [6] [7] and were followed with an increase in shoulder range of motion [4] [6] [13].

Opinions differ on when the hook plate should be removed. For distal clavicle fractures, most articles recommend removing the plate shortly after bony union [2] [4] [5] [6]. However, in a few cases no negative effects occurred when removing the plate at a later time [11] [13].

Good et al. [13] studied the effect of removal time on shoulder performance. Their results showed that the functional outcomes were good without removal of the hook plate. However, they found that after union, the earlier the plate was removed, the better the functional outcome. They compared Constant-Murley scores of patients in whom the plate was removed before 6 months and after 6 months post-operatively. They found significantly higher scores in patients that had plate removal before 6 months.

Hsu et al. [11] found that the average time for subacromial erosion to take place was 3.5 months. In other articles the average time to union has been estimated to be three months. Consequently, the plate should be removed shortly after bony union to reduce the risk of subacromial erosions.

In cases where the plate was used for AC joint injuries, it was recommended to remove the plate after three months, following ligament healing [8] [10].

4. Discussion

In this literature review, the intention was to identify the advantages of the clavicle hook plate as well as the potential complications that may be expected. Further, the suitability of the plate for different types of injuries was evaluated and information was collected on if and when to remove the plate.

The hook plate was used mainly for displaced lateral-third clavicle fractures Neer Type II and for AC ligament injuries Rockwood grade III-VI [8]. The literature review suggests that, if not treated correctly, these injuries may lead to a limited range of motion and general poor performance of the shoulder [5] [6].

The literature review pointed out that clavicle hook plating is an adequate method to treat Neer Type II distal clavicle fractures and AC joint injuries [2] [7] [8] [10] [13] [14]. Union rates and shoulder performance post-operatively have been reported to be high, especially, when the plate shape is correctly adapted to the patient anatomy [2] [7] [11].

However, the clavicle hook plate has shown high complication rates, including impingement, subacromial osteolysis, pain, and plate migration.

Therefore, plate removal is recommended to reduce the risk of these complications, which may also facilitate an increase in shoulder performance, especially range of motion. Different recommendations for time to plate removal can be found in the literature, ranging from 3 to 12 months.

Consequently, important factors of plate shape and plate removal should be taken into consideration to reduce the risk of complications. Furthermore, good surgical technique as well as proper choice of hook depth and location when implanting the plate are of critical importance.

5. Conclusion

Overall, this literature review showed that the better the plate fits the anatomy of the clavicle, the fewer complications were reported. To reduce the risk of rotator cuff tears and subacromial osteolysis, it is advisable that the plate is removed once the injury has healed. Removing the plate may also help to reduce pain, impingement and prevent subacromial osteolysis.

The results of this literature review aided in the development of the Stryker VariAx Clavicle Hook Plate. The hook is angulated slightly distal and posterior. This may lead to a better distribution of the transmitted forces over an increased implant-bone contact surface which may minimize point loading and may prevent erosion of the acromion. In addition, the plate design is thinner than first generation hook plates and is shaped anatomically, allowing for an optimal fit to the superior aspect of the clavicle.

Based on design input this medical device may have the capability to reduce the complications reported in the literature. However, clinical studies are to be conducted to confirm the benefits of these anatomically designed hook plates.

6. References

- [1] A. McConnell, D. Yoo, R. Zdero, E. Schemitsch und M. McKee, «Methods of operative fixation of the acromioclavicular joint: a biomechanical comparison.» *J Orthop Trauma*, pp. 248-53, 2007.
- [2] D. Tiren, A. J. van Bommel, D. J. Swank and F. M. van der Linden, "Hook plate fixation of acute displaced lateral clavicle fractures: mid-term results and a brief literature overview," *J Orthop Surg Res*, p. 7:2, 2012.
- [3] OCEBM Levels of Evidence Working Group, "The Oxford 2011 Levels of Evidence," Oxford Centre for Evidence-Based Medicine, 2011. [Online]. Available: <http://www.cebm.net/index.aspx?o=5653>. [Accessed 10. 03. 2014].
- [4] D. N. Bhatia and R. S. Page, "Surgical treatment of lateral clavicle fractures associated with complete coracoclavicular ligament disruption: Clinico-radiological outcomes of acromioclavicular joint sparing and spanning implants," *Int J Shoulder Surg*, no. 6(4), pp. 116-20, 2012.
- [5] S. M. Klein, B. L. Badman, C. J. Keating, D. S. Devinney, M. A. Frankle and M. A. Mighell, "Results of surgical treatment for unstable distal clavicular fractures," *J Shoulder Elbow Surg*, no. 19(7), pp. 1049-55, 2010.
- [6] H. L. Tan, J. K. Zhao, C. Qian, Y. Shi and Q. Zhou, "Clinical results of treatment using a clavicular hook plate versus a T-plate in neer type II distal clavicle fractures," *Orthopedics*, no. 35(8), pp. e1191-7, 2012.
- [7] K. Wu, C. H. Chang and R. S. Yang, "Comparing hook plates and Kirschner tension band wiring for unstable lateral clavicle fractures," *Orthopedics*, no. 34(11), pp. e718-23, 2011.
- [8] H. H. Liu, Y. J. Chou, C. H. Chen, W. T. Chia and C. Y. Wong, "Surgical treatment of acute acromioclavicular joint injuries using a modified Weaver-Dunn procedure and clavicular hook plate," *Orthopedics*, no. 33(8), 2010.
- [9] M. McKee, «Clavicle Fractures.» in *Rockwood and Green's, Fractures in Adults; Seventh Edition*, Lippincott, Philadelphia, eds., 2010.
- [10] B. Kienast, R. Thietje, C. Queitsch, J. Gille, A. P. Schulz and J. Meiners, "Mid-term results after operative treatment of rockwood grade III-V acromioclavicular joint dislocations with an AC-hook-plate," *Eur J Med Res*, no. 16(2), pp. 21-6, 2011.
- [11] T. L. Hsu, S. K. Hsu, H. M. Chen and S. T. Wang, "Comparison of hook plate and tension band wire in the treatment of distal clavicle fractures," *Orthopedics*, no. 33(12), p. 879, 2010.
- [12] C. Chen, S. Yang, K. Lin, K. Lin, Y. Tarng, J. Renn and C. Lai, "Comparison of single coracoclavicular suture fixation and hook plate for the treatment of acute unstable distal clavicle fractures," *J Orthop Surg Res*, 2014.
- [13] D. W. Good, D. F. Lui, M. Leonard, S. Morris and J. P. McElwain, "Clavicle hook plate fixation for displaced lateral-third clavicle fractures (Neer type II): a functional outcome study," *J Shoulder Elbow Surg*, no. 21(8), pp. 1045-8, 2012.
- [14] I. Bisbinas, P. Mikalef, I. Gigis, T. Beslikas, N. Panou and I. Christoforidis, "Management of distal clavicle fractures," *Acta Orthop Belg*, no. 76(2), pp. 145-9, 2010.

Publisher:
Stryker Trauma & Extremities
Stryker Trauma AG
Selzach, Switzerland

Content ID: VAX-WP-5 Rev.1

A surgeon must always rely on his or her own professional clinical judgment when deciding whether to use a particular product when treating a particular patient. Stryker does not dispense medical advice and recommends that surgeons be trained in the use of any particular product before using it in surgery.

The information presented is intended to demonstrate the breadth of Stryker product offerings. A surgeon must always refer to the package insert, product label and/or instructions for use before using any Stryker product. Products may not be available in all markets because product availability is subject to the regulatory and/or medical practices in individual markets. Please contact your Stryker representative if you have questions about the availability of Stryker products in your area.

The Clavicle Hook Plate – A Literature Review

Table 2: Overview and extracted meta-data of the studies included in this review

1 st author Year	Type of Study / Level of Evidence [3]	Injury	# of Hook Plate Patients (Female:Male)	Mean Age	Union Rate	Union Time	Complication Rate	Proposed Time of Removal	Time till Removal [months]	Constant-Murley Score	Interesting Points
Bhatia 2012 [4]	Case control / Level 4	NIIB ¹	10	34.5	90.0%	-	220% ²	after fracture union	-	-	Demonstrated the safety in relation to rotator cuff and subacromial bursa. Plate removal after fracture union is recommended; long-term clinical outcomes seem to be satisfactory after implant removal.
Bisbinas 2010 [14]	Case series / Level 4	NII ³	14	-	-	-	-	-	8.0	-	Found that a hook plate is preferable to the other treatment methods because it is reproducible, safe, and independent of the patient's reliability.
Chen 2014 [12]	Case series / Level 4	NIIB	28 (12:16)	48.3	100%	-	10.7%	-	5.5	-	No significant difference in complication rate between Mersilene tape group and Hook plate group.
Good 2012 [13]	Case series / Level 4	NII	36 (10:26)	36.2	94.4%	3 months	8.3%	<6 months	4.5	83.8	Comparison between early and late plate removal.
Hsu 2010 [11]	Case control / Level 2	NII	35 (12:23)	43.2±1.2.8	100%	14.2 weeks	62.9%	After 1 year	12.0	-	Routinely explanted the hook plate after one year, unless patient requested removal earlier. No negative effects of removing the plate late were found.
Kienast 2011 [10]	Case series / Level 3	RIV-VI ⁴	225 (51:262)	38.4	-	-	10.6%	-	2.7	92.4	Hook Plate allows early functional therapy and can avoid limitations in postoperative shoulder function.
Klein 2010 [5]	Case control / Level 3	NII	22	42	-	-	22.7%	after fracture union	-	-	Highlight the importance of a short time until surgery. It was found that the longer the time until surgery, the higher the risk for complications.
Liu 2010 [8]	Case series / Level 4	RIII-V ⁵	46 (14:32)	32.6	91.3%	-	-	3 months, with healed ligaments	3.6	88.2	Found good results with low complication rates using the hook plate for acute AC joint injuries.
Tan 2012 [6]	Case control / Level 3	NII	23 (8:15)	41.8	100%	8.75±2.55 weeks	4.3%	after fracture union	10.0	-	Plate was removed in 15 patients due to shoulder function limitations at a mean of 10 months (range, 3-14 months).
Tiren 2012 [2]	Case series / Level 4	NII	28 (7:21)	38	96.0%	-	10.7%	after fracture consolidation	6.0	97.2	Adjusting the plate to the anatomy helped minimizing complications. No relation between short term complications and mid-term functional results were found.
Wu 2012 [7]	Case control / Level 3	NII	92 (37:55)	49.3	100%	-	13.0%	immediately after bony union	5.2	90.4±4.7	Bending the plate to fit the anatomy correlated with higher Constant-Murley scores. Compared to K-wire fixation the hook plate, due to increased fracture fixation stability, provides more stable fixation, shortens the removal time and results in higher Constant scores.

¹ NIIB = Neer type IIB fracture: displaced lateral-third clavicle fracture with completely disrupted coracoclavicular ligament.

² More complications than patients are reported (22 complications, 10 patients), not clear how many patients had no, and how many had multiple complications.

³ Article is about Distal Clavicle Fractures in general, they promote the hook-plate for type II distal clavicle fractures.

⁴ RIV-VI = Rockwood grade IV-VI: Acromioclavicular joint injury with ruptured ligaments.

⁵ RIII-V = Rockwood grade III-V: Acromioclavicular joint injury with ruptured ligaments.